THE DYNAMIC SPINE: A MULTI-MODAL APPROACH TO CHIROPRACTIC CARE

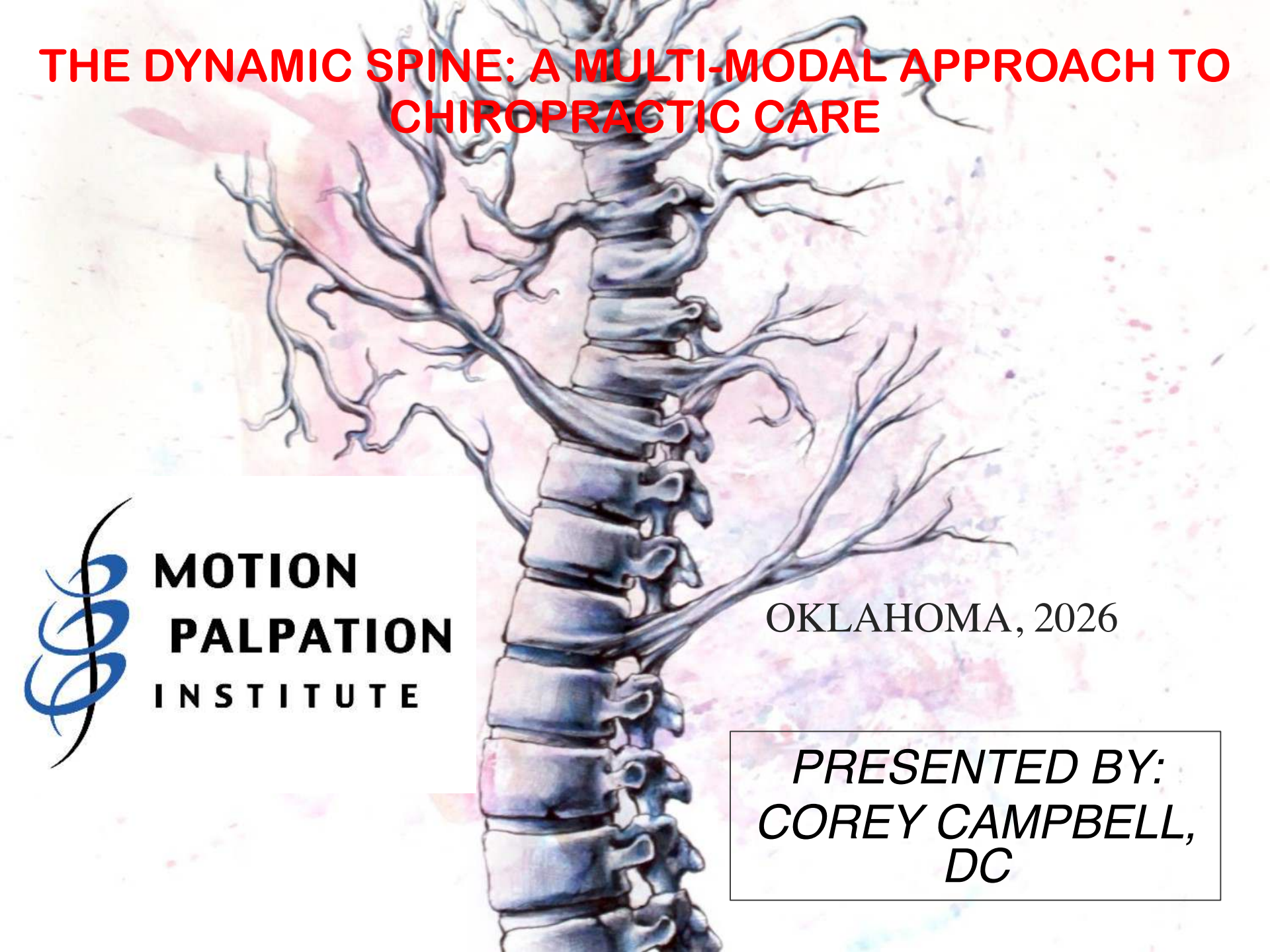

MOTION PALPATION INSTITUTE

OKLAHOMA, 2026

PRESENTED BY:
COREY CAMPBELL, DC

Motion Palpation Institute

The Motion Palpation Institute is the leading organization that unites the entire spectrum of today's functional chiropractic techniques to produce proven clinical and financial success.

Please Note: No filming or taping of MPI classes. Please do not ask for the power point notes. Thank you.

Any and all demonstrations during the class are just that. There will be no diagnosis or will there be any treatment allowed on a doctor-patient basis

Disclaimer: All presented material is for educational and demonstrational use only. Diagnostic and treatment recommendations may be discussed but are in no way intended to develop a doctor patient relationship.

MOTION PALPATION INSTITUTE

MOTION PALPATION INSTITUTE

THE VISION AND AGENDA OF MPI

The Motion Palpation Institute is the leading organization that unites the entire spectrum of today's functional chiropractic techniques to produce clinical and financial success.

- *1. To provide classes that help develop DC's palpation and adjusting skills to a level that is unmatched and unparalleled. (Help create the best palpators and adjustors on the planet).*
- *2. Do MORE of #1.*
- *3. To provide classes that integrate other useful manual therapy and rehab techniques in a chiropractic friendly way. (Not many do this).*
- *4. To deliver these classes with Character, Humility, Humor, and Compassion.*

The MPI Model - Practice Fulfillment

- Practice built on patient results and referrals.
- Practice based on model's success retaining patients.
- Venue for mastering skills, establishing competitive differentiators, & providing best care.
- Flexible but based on the essence of what is Chiropractic
- NOT A PHILOSOPHY or DOGMATIC!
- “Circle the wagons and shoot inward.”

-We can change this!!



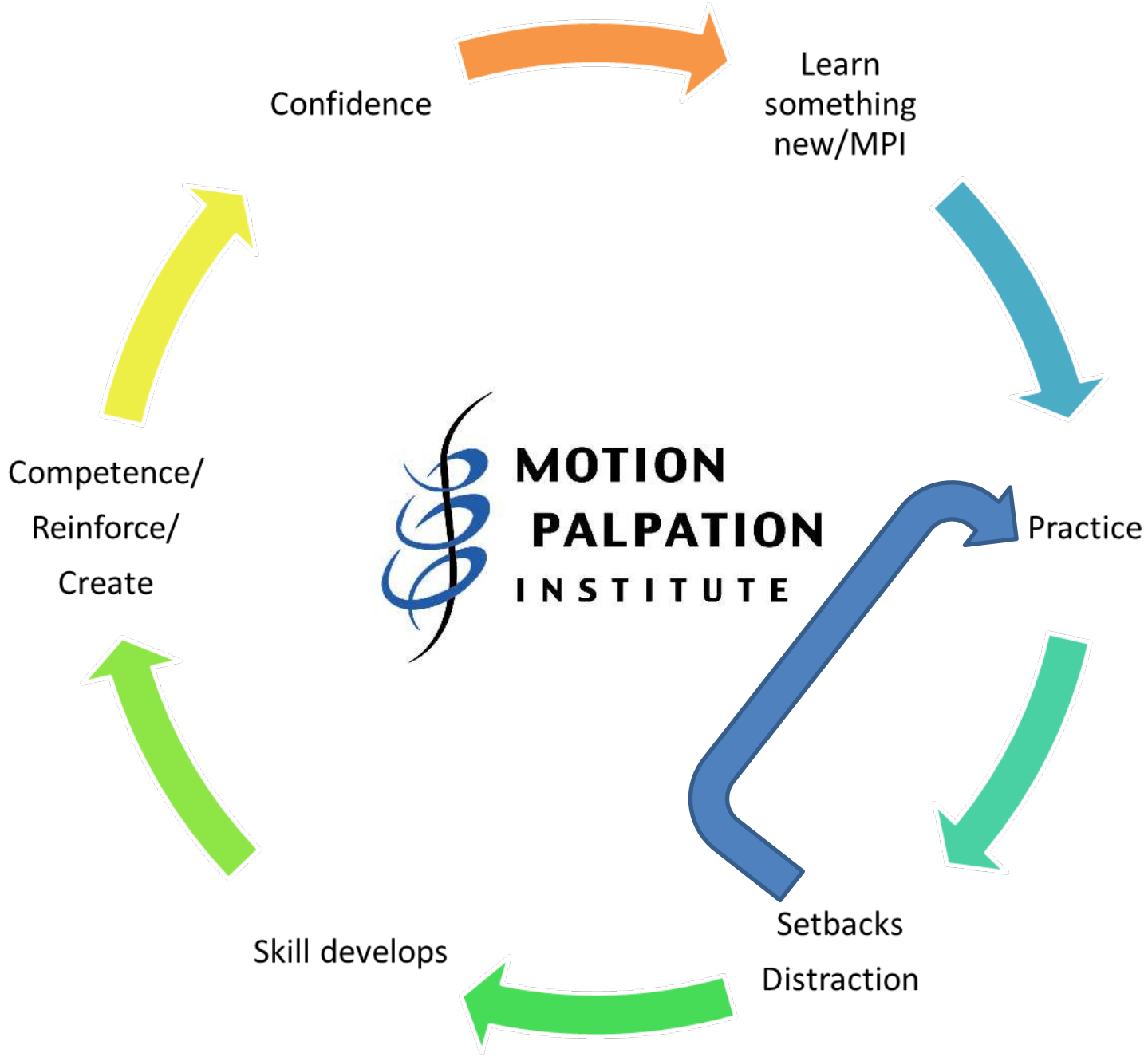
Confidence
Learn something new/MPI
Practice
Setbacks
Distraction
Skill develops
Competence/
Reinforce/
Create
MOTION
PALPATION
INSTITUTE

STRUGGLE & PROGRESS

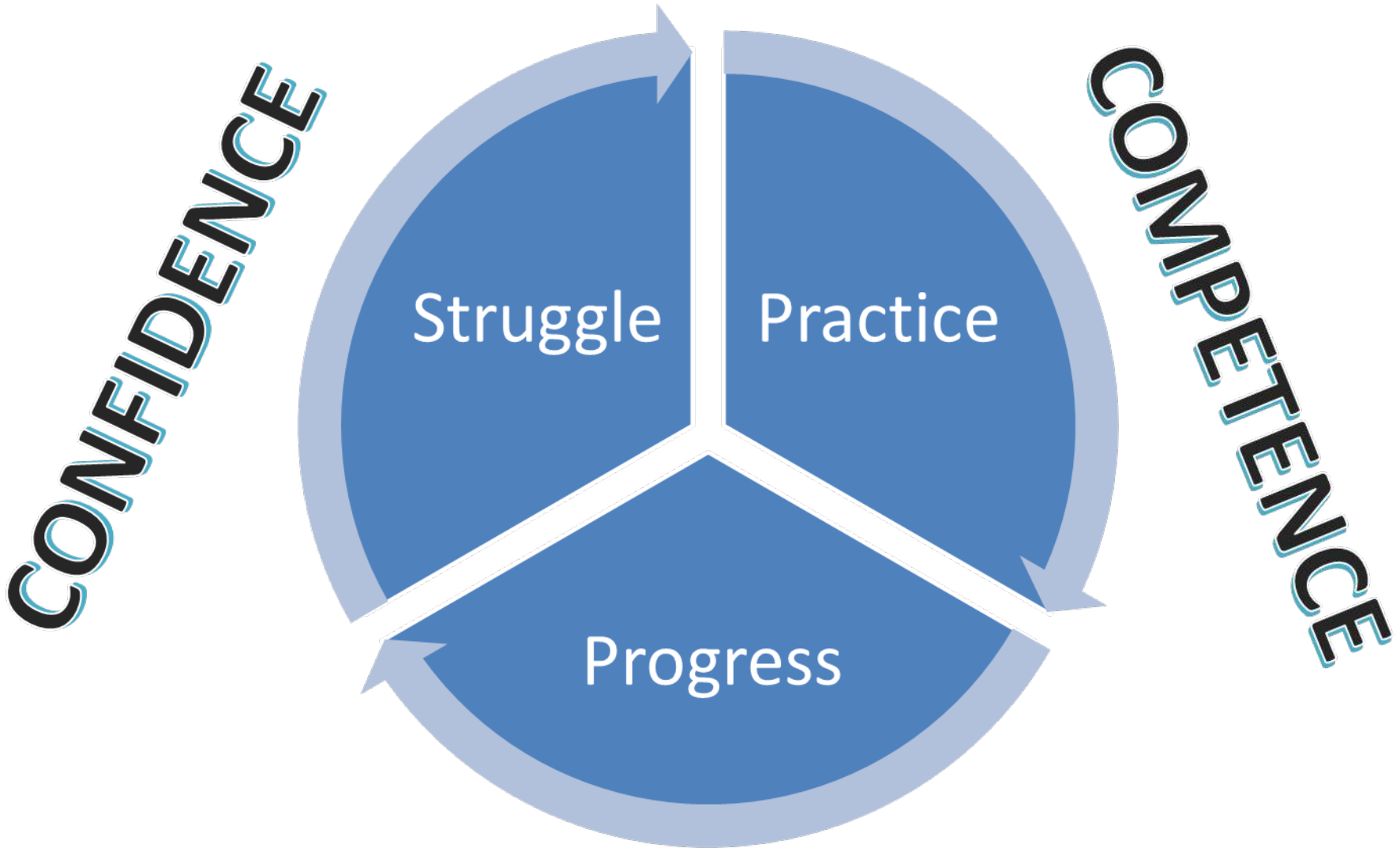

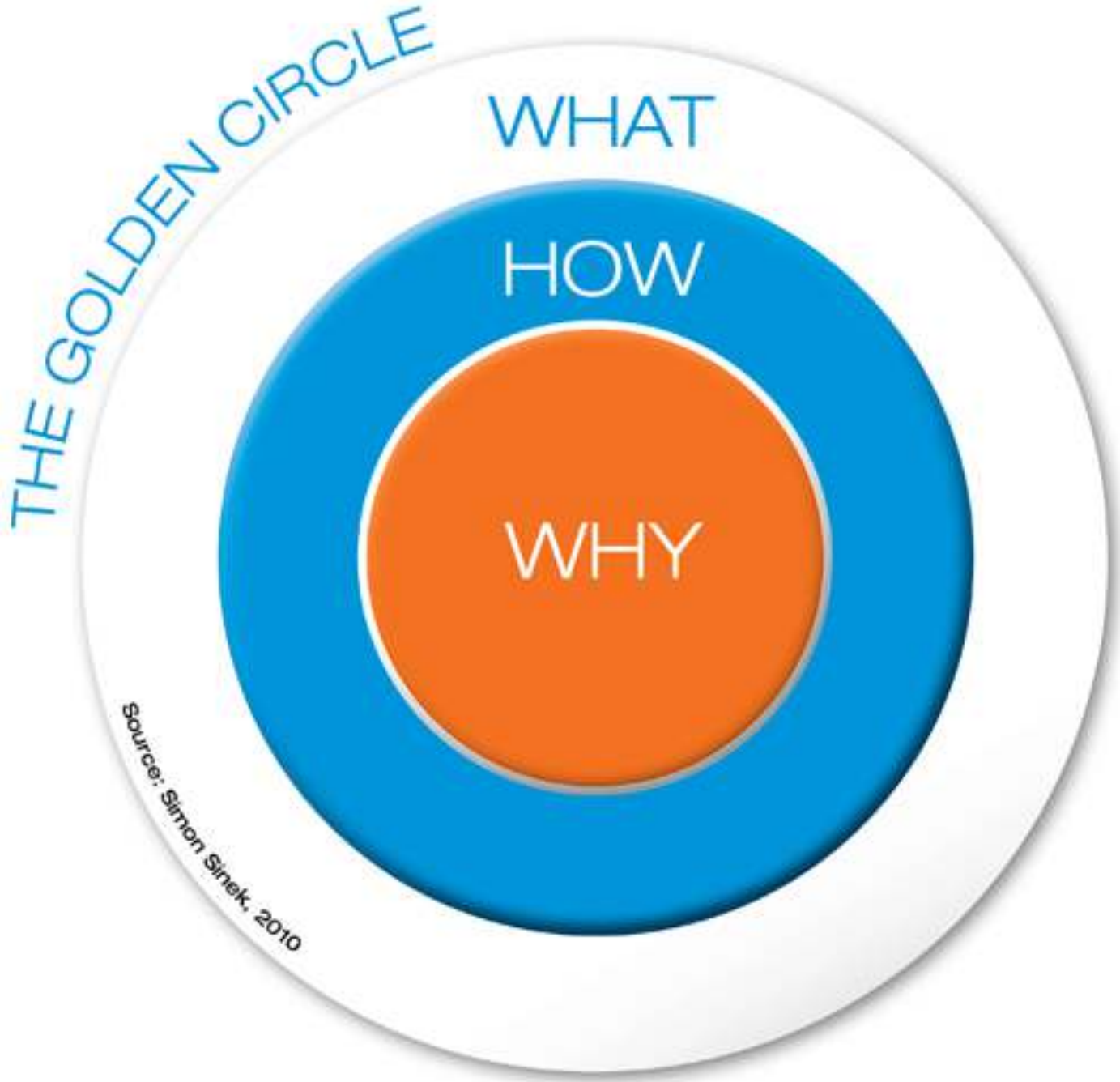
THE GOLDEN CIRCLE
WHAT
HOW
WHY
Source: Simon Sinek, 2010

THRIVING DC-*KEVIN CHRISTIE*

- The 3- legged stool of the thriving chiropractor:
- 1. Marketing
- 2. Business
- 3. **CLINICAL SKILL**
  - **HAND SKILLS**
  - **HEAD SKILL (CLINICAL DI**
  - **HEART SKILL (COMMUNICATION/COMPASSION)**





"The hand is the greatest diagnostic and therapeutic tool that has ever been, or will be, invented."- Karel Lewit

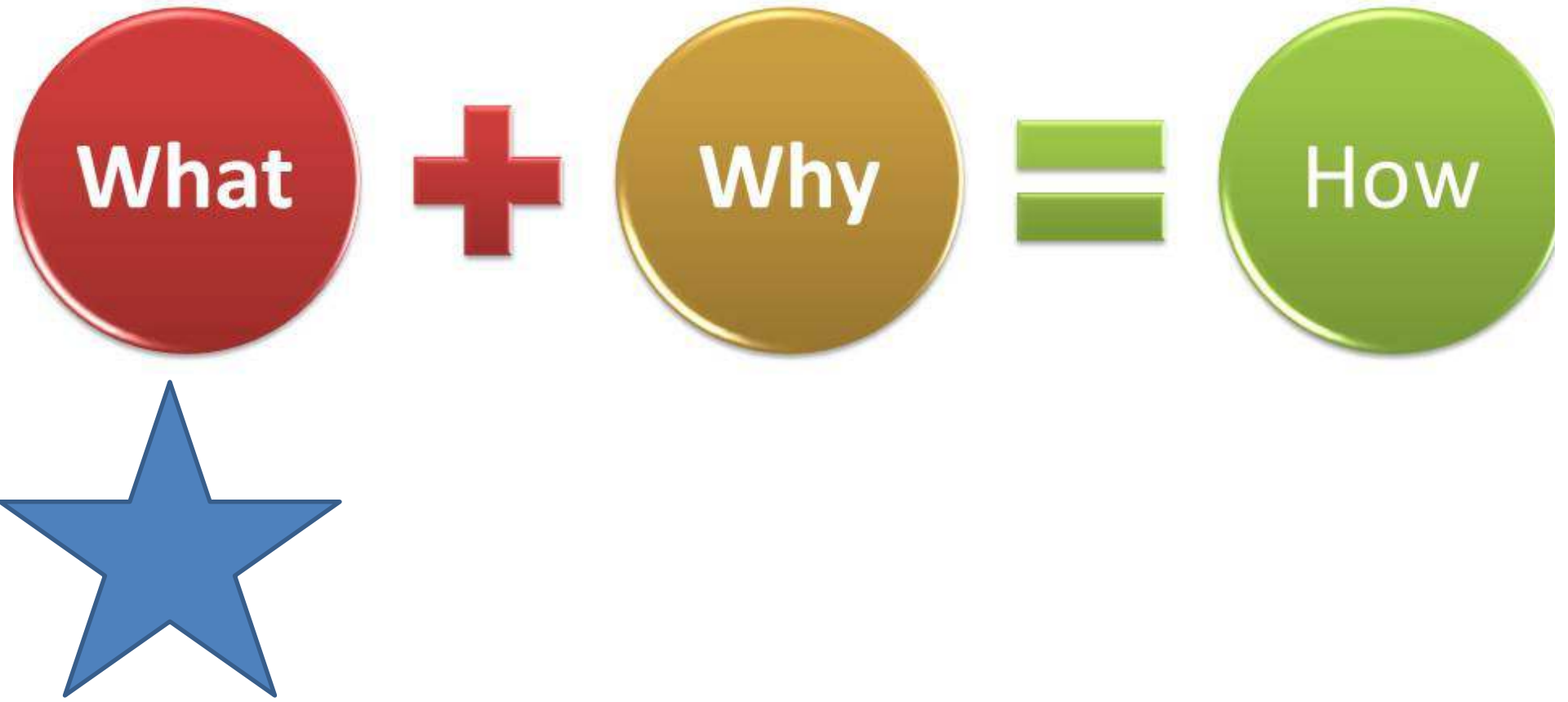
What
Why
How

Subluxation: (from Webster's)

noun sub·lux·a·tion \ˌsə-ˌbləkˈsā-shən\



Definition of *subluxation*

1.: partial dislocation (as of one of the bones in a joint)

- **“ SYMMETRY AND EQUALITY ARE *NOT* THE ORDER OF BIOLOGICAL STRUCTURES; ADAPATATION IS.”**

  – *Celenza, FV. International Journ of Peridontics and Restorative Denistry. 1984*

MPI's SPIN ON IT

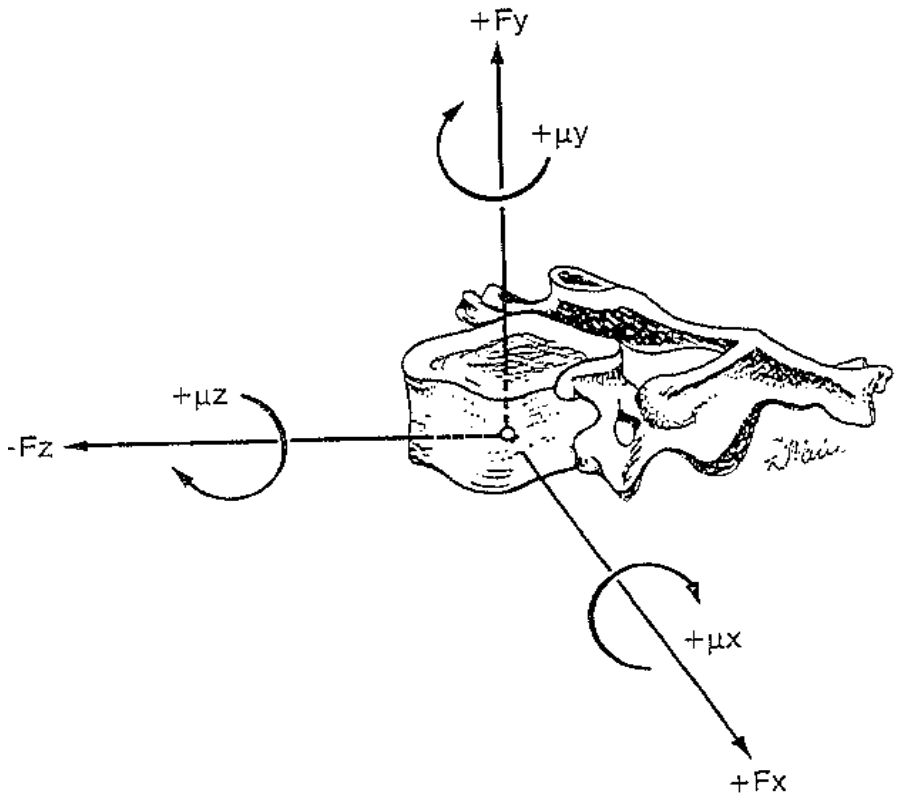

- All joints rotate around 3 axis'. Muscle and position can affect changes in these axis'.
- Anatomy and joint mechanics don't lie.
- No matter what our chosen technique, it is our obligation to be experts at how muscles and joints function.

THE SPINAL ENGINE

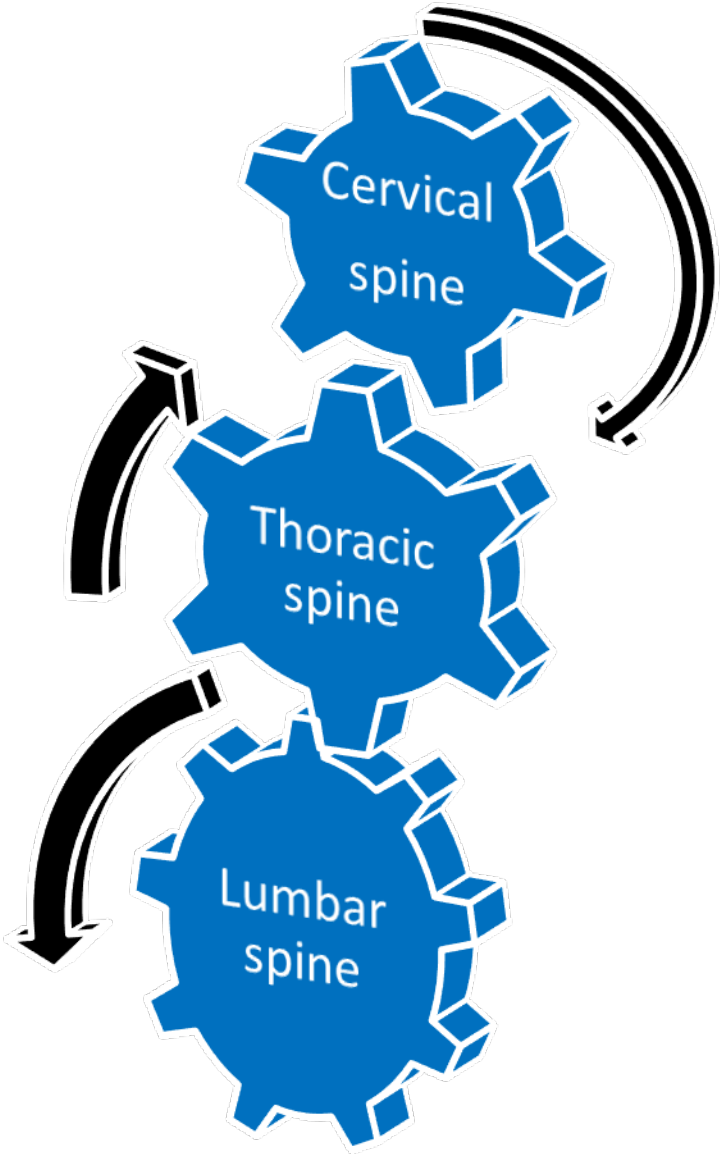

- Shared motion and load transfer is the goal.

- Efficiency= Appropriate amount of stability needed for the greatest amount of motion.- (*with the least amount of energy expended)*

"NOT ALL VERTEBRAL SEGMENTS HAVE THE SAME IMPORTANCE, WE THEREFORE MUST SPEAK OF KEY REGIONS OR SEGMENTS OF THE SPINE" (LEWIT, 1999)

- THESE ARE MOSTLY TRANSITIONAL AREAS WHERE THE FUNCTION OF THE SPINE CHANGES



- CRANIOCERVICAL, CERVICOTHORACIC, THORACOLUMBAR,LUMBOSACRAL, AND FEET

1.CT 2.TL 3.HIPS/FEET 4. LS 5. CO-C2 (sorry BJ and DD)

- THIS IS WHERE PRIMARY RESTRICTIONS OCCUR AND WHERE MOST ADJUSTMENTS SHOULD BE GIVEN (EVEN IF PAIN IS NOT THERE)

"Common Sense isn't always Common Practice"
-Burchard



Arch Phys Med Rehabil Vol 86, September 2005

ORIGINAL ARTICLE

Lumbar Spine Segmental Mobility Assessment: An Examination of Validity for Determining Intervention Strategies in Patients With Low Back Pain

Julie M. Fritz, PhD, PT, ATC, Julie M. Whitman, DSc, PT, OCS, John D. Childs, PhD, PT, OCS, CSCS

Conclusions: Patients with LBP judged to have lumbar hypomobility experienced greater benefit from an intervention including manipulation; those judged to have hypermobility were more likely to benefit from a stabilization exercise program.



“BACKING” WHAT WE DO

- ***Degenerative Changes Following Spinal Fixation in a Small Animal Model***

  JMPT March/April 2004, p.141-154

  Cramer, Fournier, Henderson, & Wolcott

- ***Zygapophyseal Joint Adhesions After Induced Hypomobility*** Cramer, Henderson, Little, Daley, & Grieve

  JMPT September 2010, Vol. 33, #7, p. 508-518

- ~~***Spinal Manipulation, Medication, or Home Exercise With Advice for Acute and Subacute Neck Pain***~~

  A Randomized Trial

- ***G. Bronfort, DC PhD***

Reliability of accessory motion testing at the carpal joints

Staes, Banks, De Smet, Daniels, & Carels

June 2009, Manual Therapy Journal – Vol 14, # 3, p. 292-298

Upper Cervical and Upper Thoracic Thrust Manipulation Versus Nonthrust Mobilization in Patients With Mechanical Neck Pain: A Multicenter Randomized Clinical Trial

Journal of orthopaedic *& sports physical therapy | volume 42 | #1 | Jan, 2012*

Chiropractic is Safe and Effective for Back Pain During Pregnancy

Peterson CK, Mühlemann D, Humphreys BK. Outcomes of pregnant patients with low back pain undergoing chiropractic treatment: a prospective cohort study with short term, medium term and 1 year follow-up. Chiropractic and Manual Therapies 2014;22(1):15.

This study states that 85% of pregnant women reported relief from back pain after receiving chiropractic adjustments.

Effects of the Adjustment - Neurological

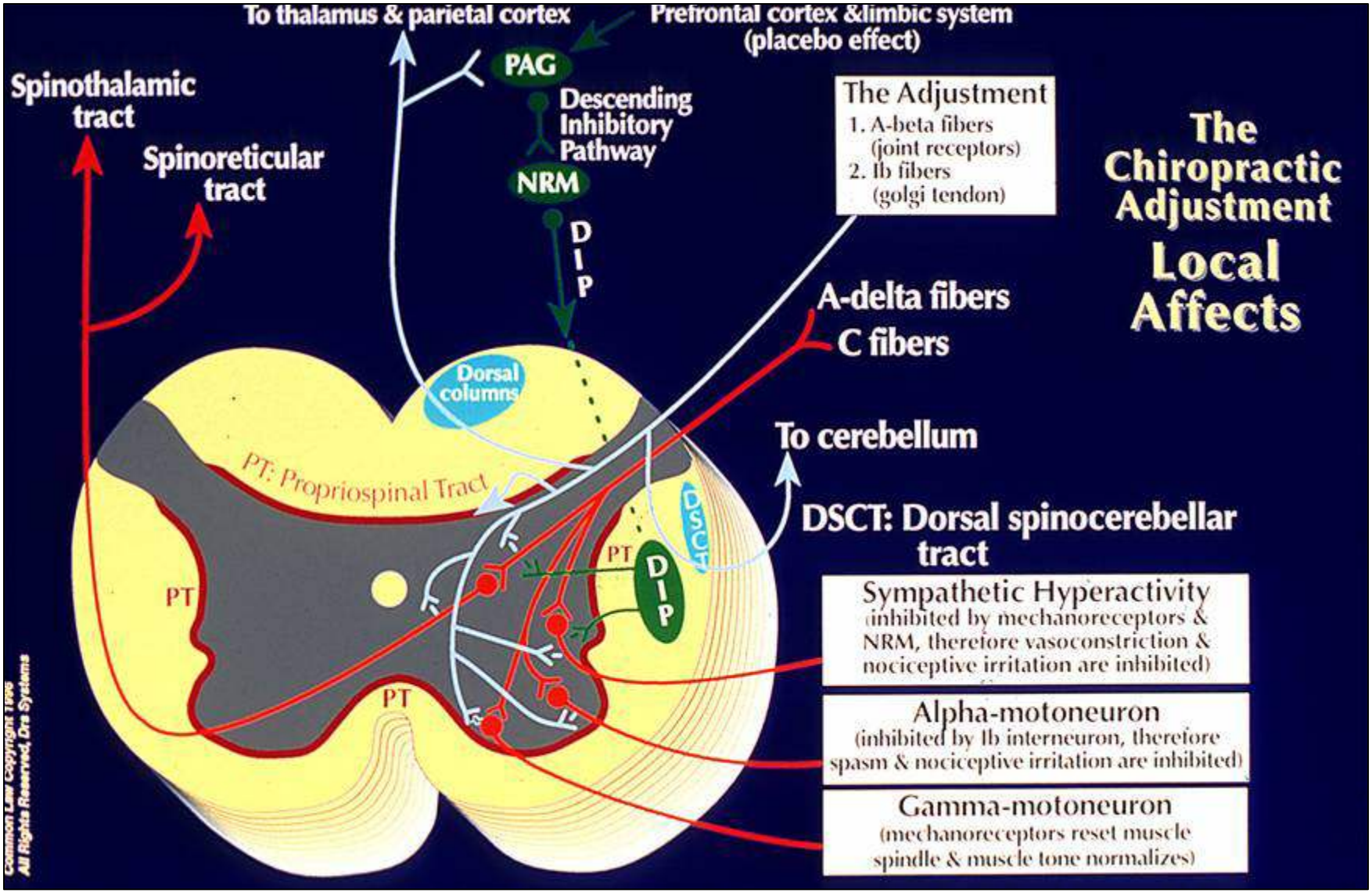

More than Mechanics

- **Correlation of Somatic Dysfunction With Gastrointestinal Endoscopic Findings: An Observational Study.** Snider KT, et al. J Am Osteopath Assoc. 2016.
  - somatic dysfunction and abnormal endoscopic findings.
- **Changes in H-reflex and V-waves following spinal manipulation.** Niazi IK, et al. Exp Brain Res. 2015.
  - **The improvements in MVC following spinal manipulation are likely attributed to increased descending drive and/or modulation in afferents. Spinal manipulation appears to prevent fatigue developed during maximal contractions.**
- **Effect of Spinal Manipulation on Pelvic Floor Functional Changes in Pregnant and Nonpregnant Women: A Preliminary Study. –** Haavik,H et al. JMPT. June 2016

HVLA & Neurology

- Recent literature (4, 5) has re-examined our beliefs about how manipulation works. Traditional theories regarding the underlying mechanisms of manipulation include primarily structural concepts (4) – disruption of "adhesions", release of trapped intra-articular material in facets, realignment of spinal structure, and so on.
- **More recent explanations tend to focus on neurophysiologic effects, including mechanoreceptor stimulation and motor neuron excitability modulation (5), reflecting the unique sensory input caused by a high-velocity thrust. The exact answer is not yet known, but the most compelling evidence to date lies on the neurophysiologic end of the spectrum. Such responses seem dependent on the velocity and amplitude of the force, further emphasizing that from a research (and clinical) perspective, close attention must be paid to distinguishing between manipulation and mobilization.**

Comparison of the effectiveness of three manual physical therapy techniques in a subgroup of patients with low back pain who satisfy a Clinical Prediction Rule: A randomized clinical trial – Cleland JA, Fritz JM, Kulig K et al. -Spine 2009; 34(25): 2720-2729

NSAIDS VS. HVLA

Spinal high-velocity low amplitude manipulation in acute nonspecific low back pain: A double-blinded randomized controlled trial in comparison with diclofenac and placebo; von Heymann W, Schloemer P, Timm J et al.; Spine 2013; 38(7): 540-8.; MAY 2013

- **The purpose of this study was to determine whether the treatment of acute LBP by spinal manipulation is equal to or better than NSAID medication, and whether active intervention is more useful than rescue medication only.**

  A large number of patients were excluded from this trial or refused to sign the informed consent, totaling about 5 times the number of subjects that were included. Ultimately, however, 101 patients were recruited: 69 during the initial 3-arm phase and another 32 during the 2-arm phase where only the active therapies were compared. Only 93 subjects were evaluable, with 22 of them undergoing placebo treatment, 36 diclofenac, and 35 spinal manipulation.
  Results:
  • There were significant differences between the treatment groups at follow-up, with the spinal manipulation group showing faster and greater reduction in the RMS. The mean reduction (± SD) from pretreatment values were 7.71 ± 4.88 after spinal manipulation and 4.75 ± 4.93 in the NSAID group.
  • The VAS for pain showed similar results, with subjects noticing faster and greater reductions of pain after manipulation.
  • As well, the somatic part of the SF-12 inventory indicated that the subjects experienced better quality of life after the spinal manipulation when compared to diclofenac. However, the median values of the psychological subscale of the SF-12 inventory did not differ between the 2 groups.
  • Patients in the NSAID group took almost 3 times as many rescue medication tablets than those in the manipulation group and the number of days taking the tablets was almost twice as high. However, there was a large variation between subjects, so the differences were not statistically significant.
  • No unexpected adverse events were reported in either of the groups.

- **The comparison of the treatments with placebo in the interim analysis was very strong in favor of both manipulation and NSAIDs. Furthermore, the superiority of manipulation over diclofenac in the final analysis was highly significant, which was true for the primary as well as the secondary variables.**

Impact or Advancement?

* ***Magnetic resonance imaging zygapophyseal joint space changes (gapping) in low back pain patients following spinal manipulation and side-posture positioning: a randomized controlled mechanisms trial with blinding.*** Cramer, et.al JMPT 2013 May
  - Showed joint gapping post-manipulation under MRI
- ***Physiological Responses to Spinal Manipulation Therapy: Investigation of the Relationship Between Electromyographic Responses and Peak Force*** JMPT, November 2013;
  - The study confirmed the presence of a local paraspinal EMG response after SMT and highlighted the linear relationship between the SMT peak force and paraspinal muscle activation.
- ***Outcomes of MRI-Confirmed Symptomatic Cervical Disk Herniation Patients treated with HVLA SMT:A prospective Cohort Study with 3-month follow up.*** JMPT 2013 -This study showed patients with confirmed cervical disc herniation do well with HVLA immediately (55% at 2 weeks and 68% at 1 month improvement with only 1 getting worse) but at 3 months 85% of the patients improved in 3 measurable areas. All of which was significantly better than the control groups and the group getting normal standard care.
- ***Altertions in cortical and cerebellar motor processing in subclinical neck pain patients following spinal manipulation*** Julian Daligadu, MHSc,a Heidi Haavik, -JMPT 2013
  - Subclinical neck pain patients have altered CBI when compared with healthy controls, and spinal manipulation before a motor sequence learning task changes the CBI pattern to one similar to healthy controls.

Your Brain on SMT

- **Cerebral metabolic changes in men after chiropractic spinal manipulation for neck pain.** Tashiro M, et al. Altern Ther Health Med. 2011 Nov-Dec;17(6):12-7.
  - *Changes in Sympathetic System Markers*
- **Alteration in cortical and cerebellar motor processin subclinical neck pain patients following spinal manip** Julian Daligadu, MHSc,a Heidi Haavik, -JMPT 2013
  - *Normalization of motor skills.*
- **Peripheral oxidative stress blood markers in patients chronic back or neck pain treated with HVLA**. *JMPT,2014 Horst A, Moraes MS, et al*

-Increased anti-oxidant production



Cavitation

- Cavitation is neither required nor detrimental to joint motion.
- “We need to liberate ourselves and our patients from the cavitation.” –Walter Herzog
- “Motor and sensory function are closely inter-related.” Pavel Kolar
- Can we improve this?


What
Why
How

“Most of you have spent years studying sciences and have learned to rely heavily upon your rational, reasoning mind. You probably have been convinced that the information which your hands can give you is unreliable. You may consider facts to be reliable only when that are printed on a computer sheet, projected on a screen or read from the indicator of an electric device. In order to use your hands and to begin to develop them as reliable instruments for diagnosis and treatment, you must learn to trust them and the information they can give you.”

John Upledger 1987



WHAT TO ADJUST?

WHEN TO ADJUST VS. MOBILIZE VS. MODALITY OR NOTHING?

HOW TO PRIORITIZE WHILE IN SCHOOL OR PRACTICE?

Palpation

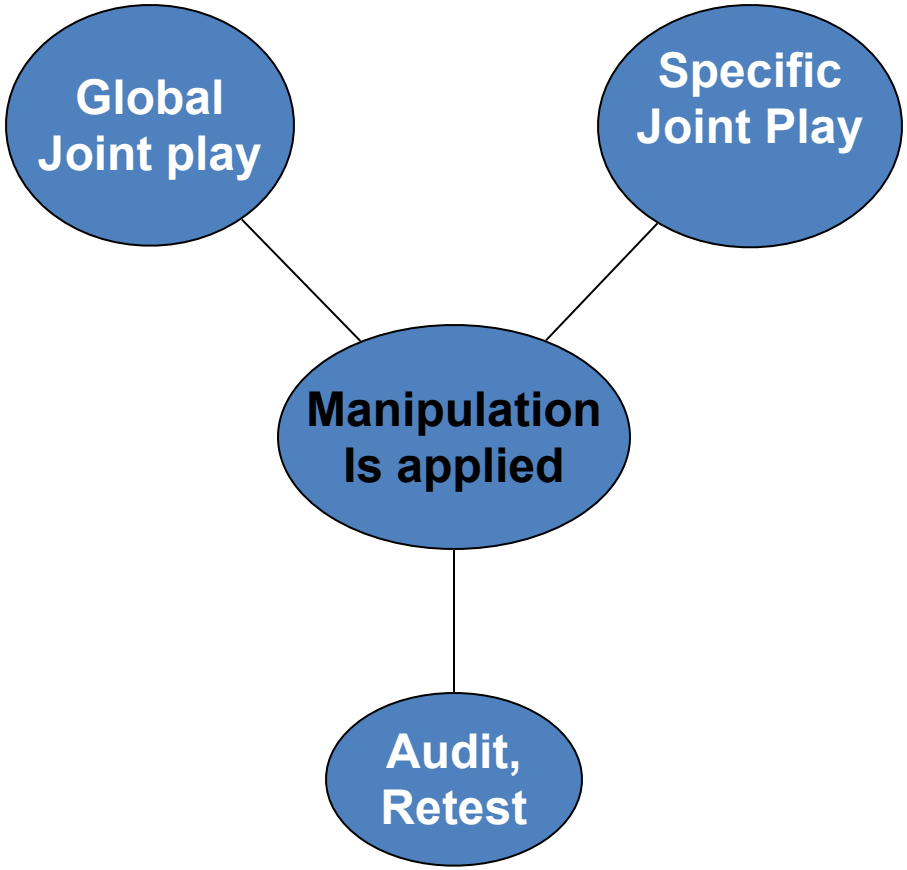

- "Restriction of motion of one part of the spine causes increased motion of part of the spine" (Nordin, Frankel, 1989)

Palpation options

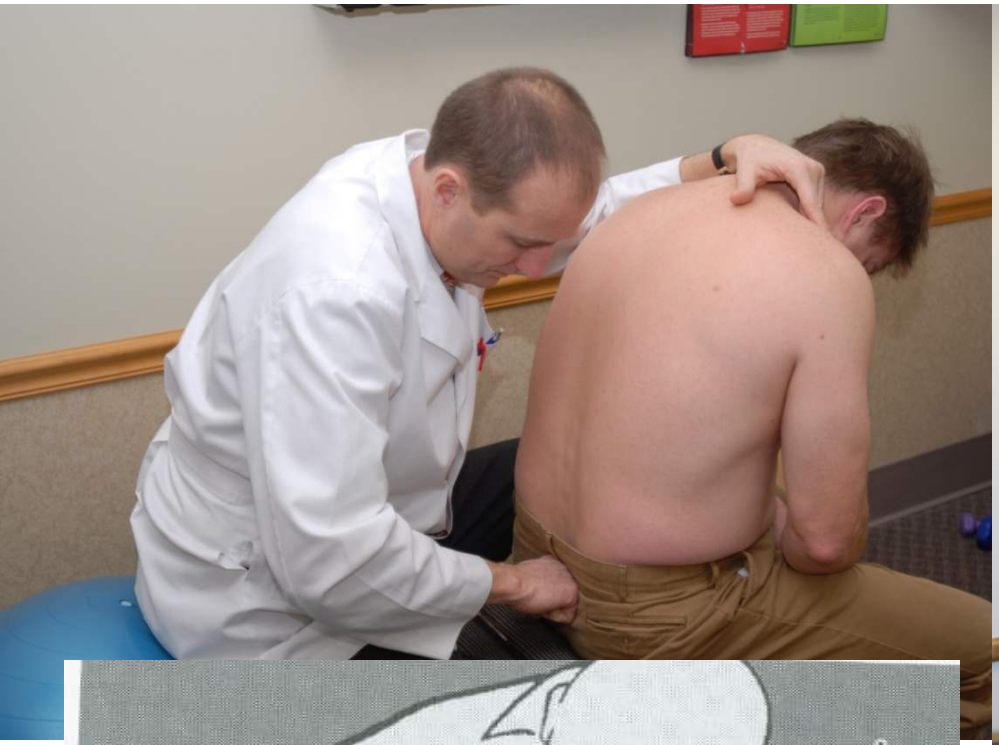





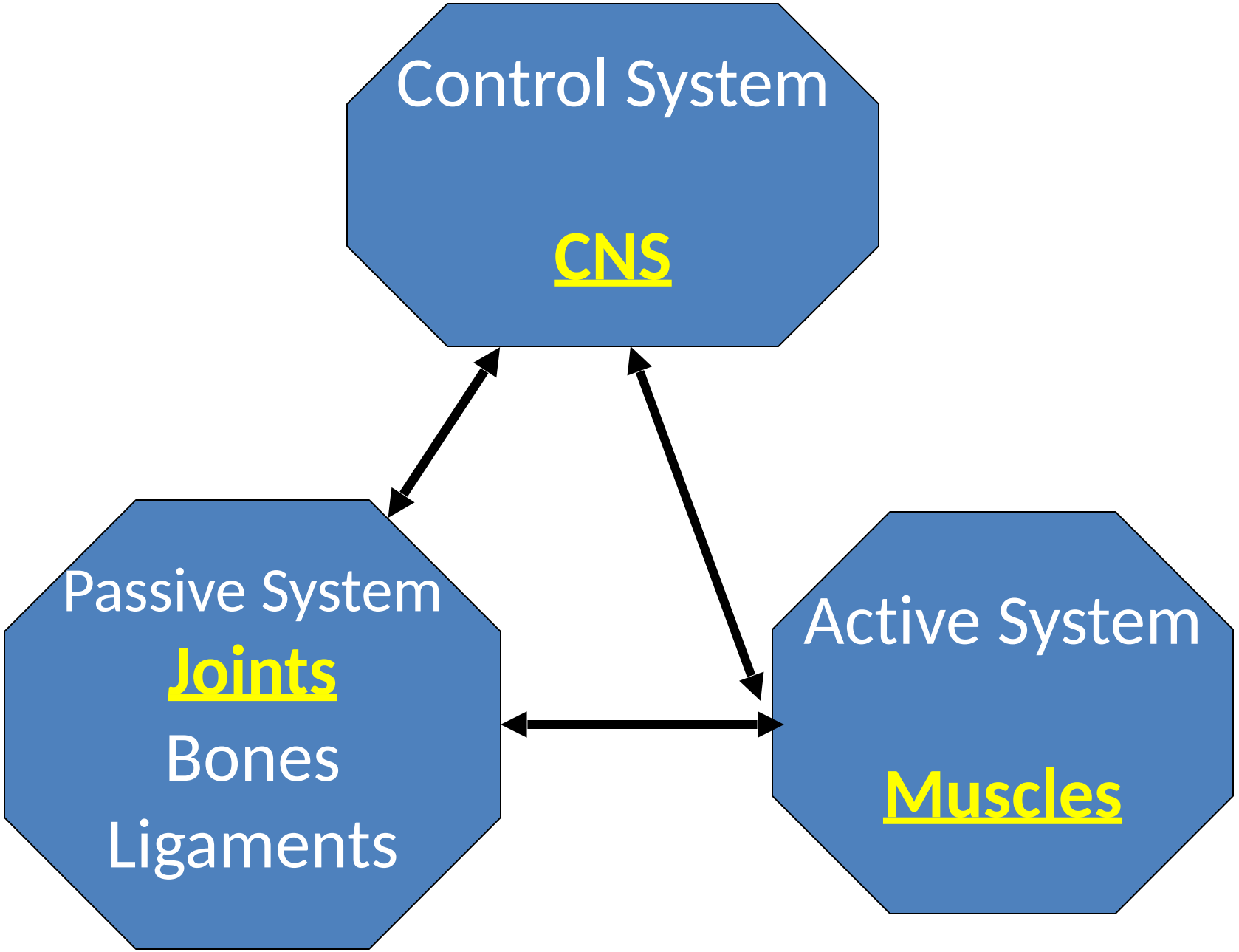
Control System
CNS
Passive System
Joints
Bones
Ligaments
Active System
Muscles

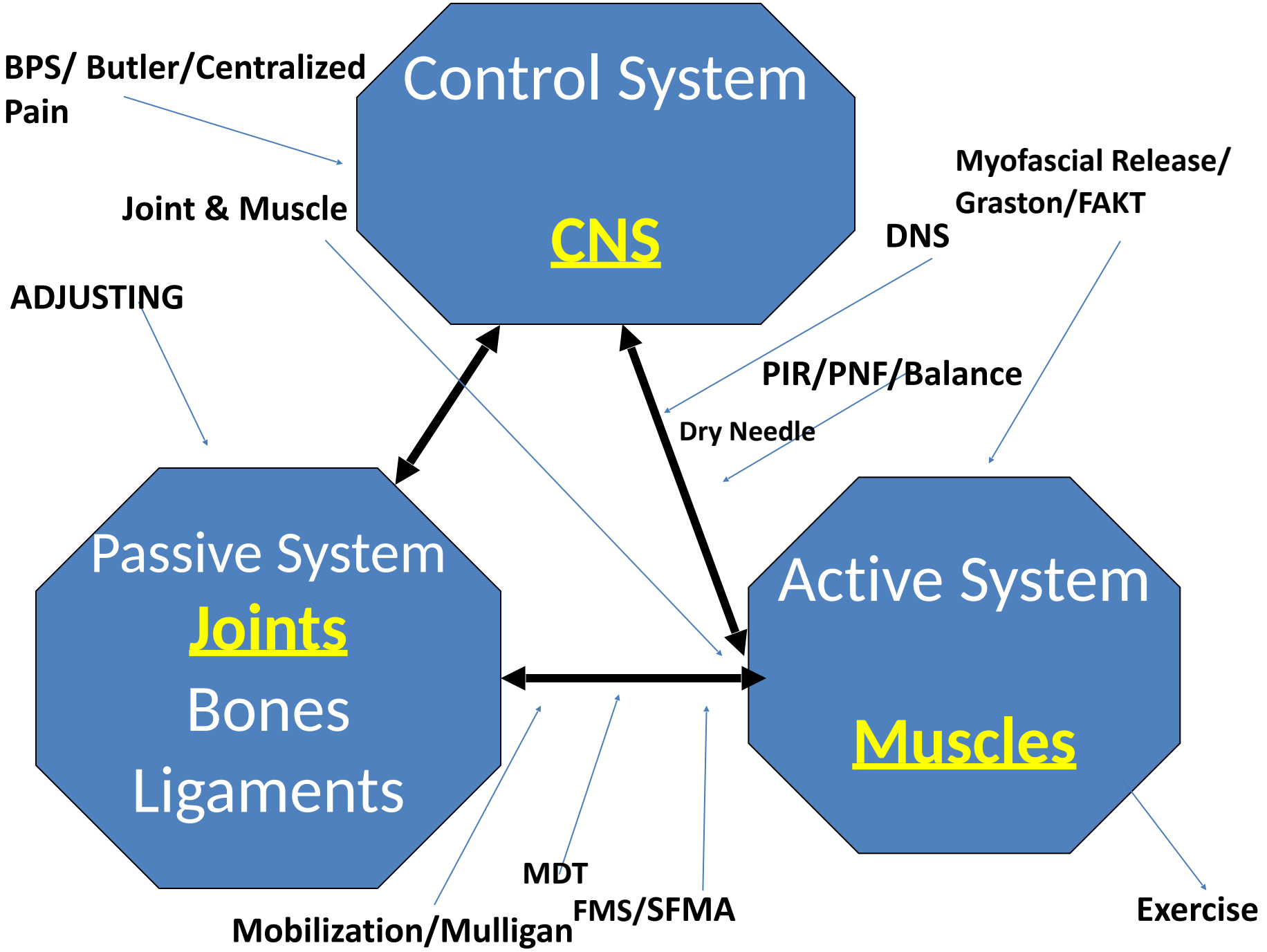
BPS/ Butler/Centralized Pain
Control System
CNS
Joint & Muscle
Myofascial Release/ Graston/FAKT
DNS
ADJUSTING
PIR/PNF/Balance
Dry Needle
Passive System
Joints
Bones
Ligaments
Active System
Muscles
MDT
FMS/SFMA
Mobilization/Mulligan
Exercise

FUNCTIONAL TRIAGE

EXAMINATION & ASSESSMENT

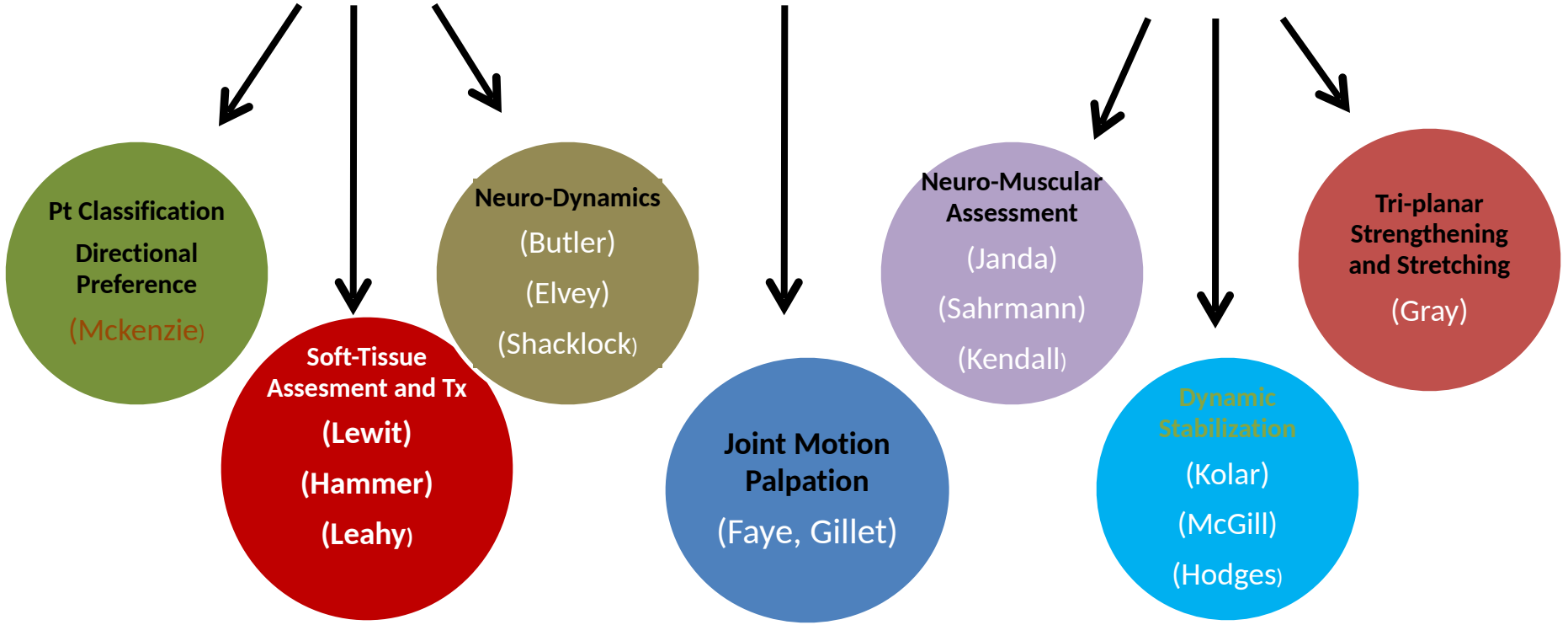

TREATMENT PRIORITIZATION

(an example)

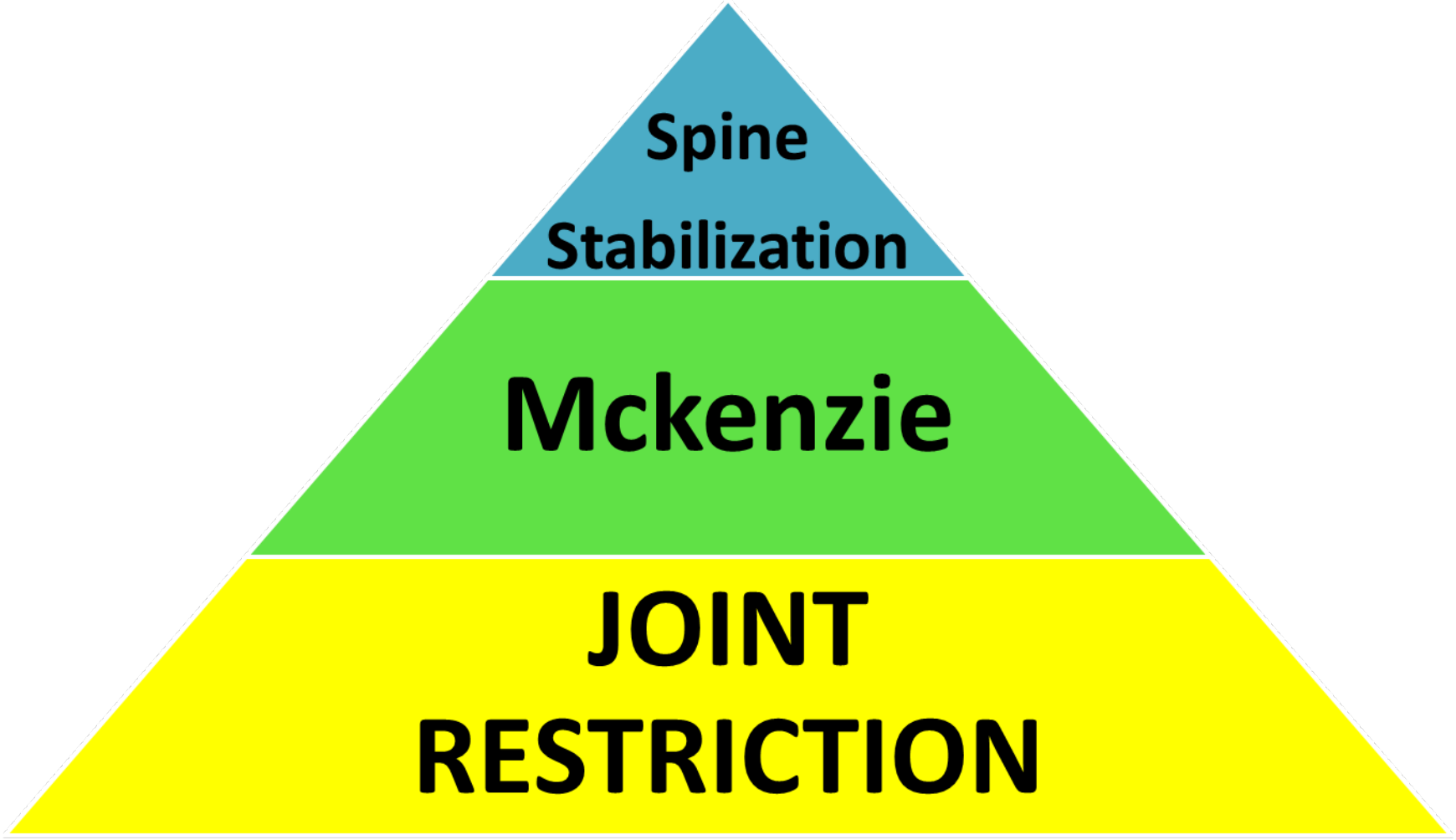

Modern Day DC/MPI Model

- Great Hands:
  - Palpation & Adjusting>>> "**Be so good they can't ignore you." –Steve Martin**
- Puzzle-Solver:
  - Palpation/Functional Testing/Neuro/Ortho/ End-Range Loading>>> ***Do a Great Exam***
- Nutrition/Lifestyle:
  - DEFLAME Guide/ Stress Relief
- Things you can't measure:
  - Ability to Communicate, Compassion, Congruence Empathy, Humor, Focus, Presence, Grit, Passion, Purpose, BadAssedNess

What Makes Great Adjusters



- The ability to relax completely then contract ballistically
- Developing “power” from within (IAP and spine stiffness)
- Speed=Relaxation and stability (being close).
  - “Stay tight to stay light.”
- Set-up & knowing exactly how joints work

Adding FORCE to a MOTION that is already in progress.

Leverage vs. Poseology

- Being a good L-spine and Pelvis adjuster is ALL about <u>great patient positioning</u> and putting yourself in an athletic position that allows for:

  - **1. Control**
  - **2. Relaxation**
  - **3. Speed/Quickness**



"The kid with the best technique wins the 1st period, the kid with the best conditioning wins the 2nd period, the kid with the biggest heart wins the 3rd period." ***–DAN GABLE***



"The hand is the greatest diagnostic and therapeutic tool that has ever been, or will be, invented."- Karel Lewit

Concepts – Palpation
THE SEATED SCAN

Palpation Rules:

Patient must be in a neutral posture to allow for full normal physiological motion to occur

CUES:

Attempt to stay light.

Think of snapping a rug.

Wave-like motion in the spine.

Gliding the vertebra on the disc.

Have a purpose. Don't be sloppy.



T4 SCAN





Patient hands interlaced behind the head→Glide the pt. forward→ suppor your palpating arm on your knee→ Glide forward and feel for approximati of the SP's and anterior glide and a spongy feel.

"The problem with palpation is people don't want to take the time required to get good at it."
Karel Lewitt, MD

EXAMPLE

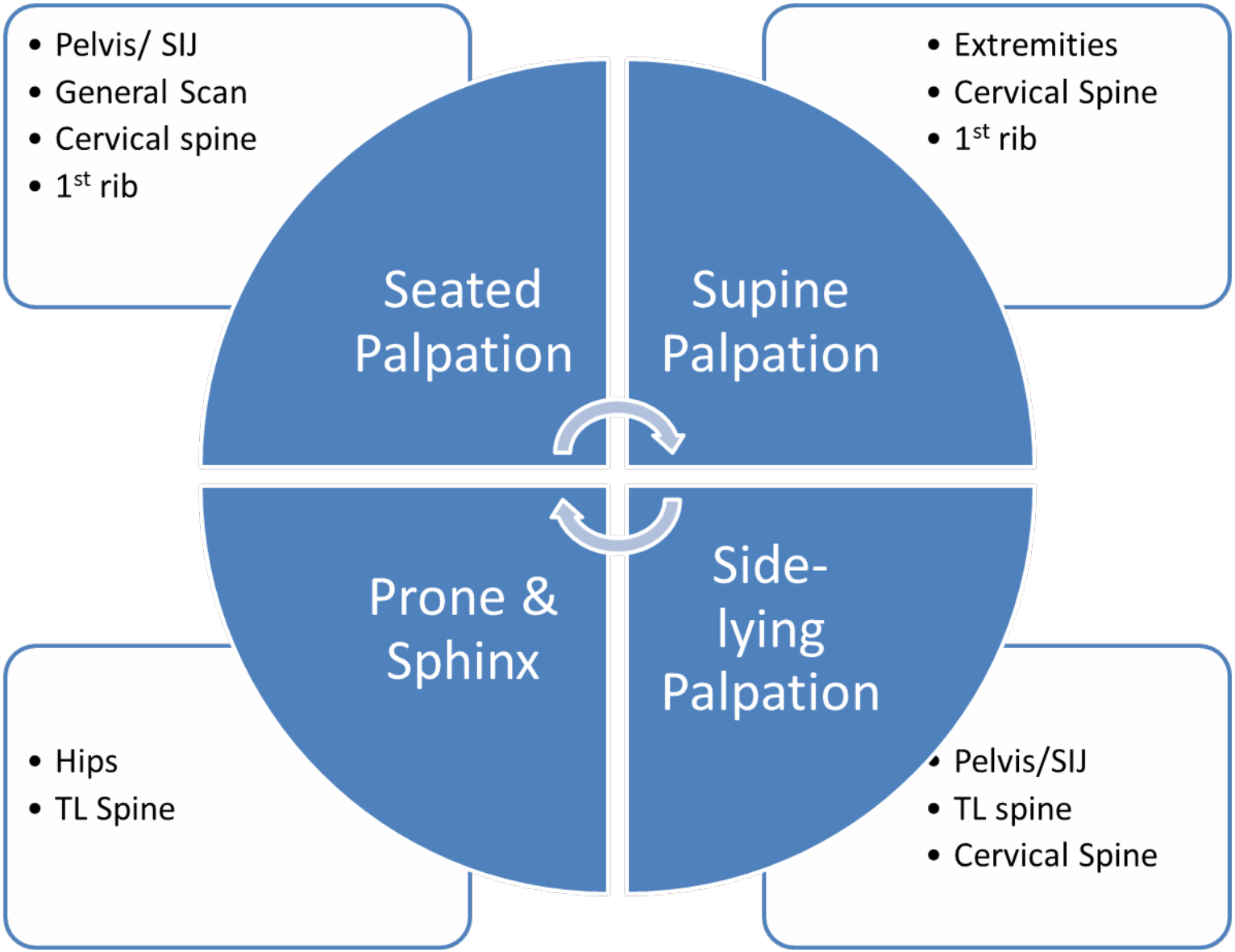

Lab 1

THE SACRUM

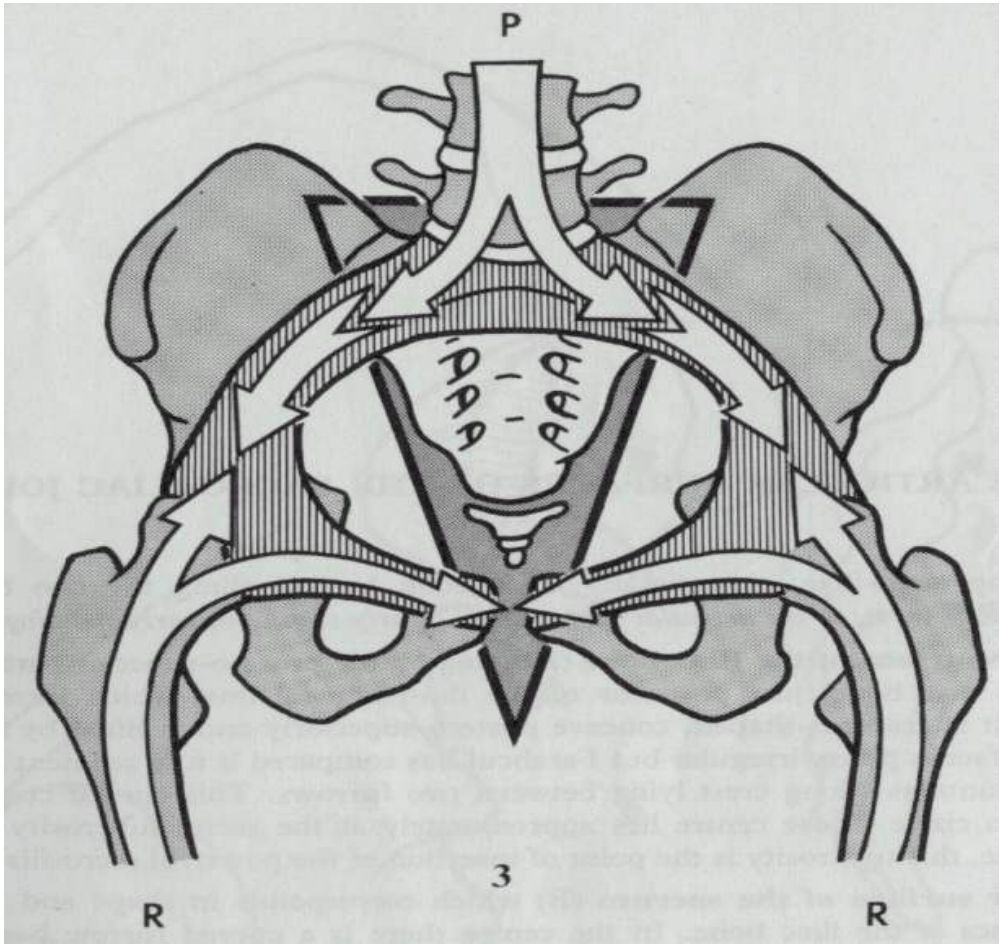



NUTATION

- Movement of sacrum between ilia involving anterior nodding motion
- Innominates will move posterior
- Associated with an extended lumbar spine
- Loads interosseous and sacrotuberous ligaments
- Increase SIJ compression
- Synonymous with stability (hee strike), and increased lordosis



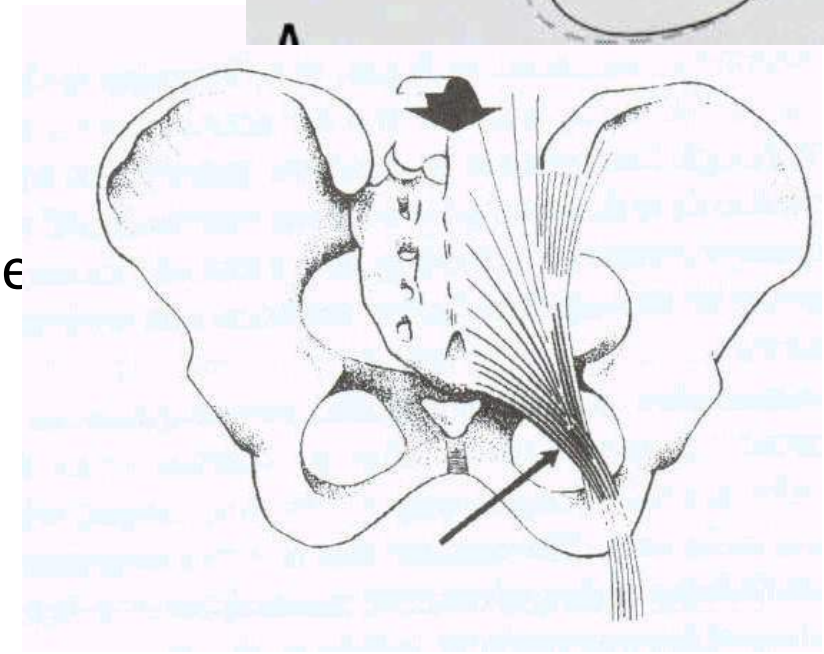

COUNTERNUTATION

- Movement of sacrum between the ilia in a posterior direction
- Innominates will move anterior
- Associated with a flexed lumbar spine
- Loads long dorsal sacral ligament
- SIJ instability, increased motion, and loss of lordosis or flat back
- Sitting and Laying down

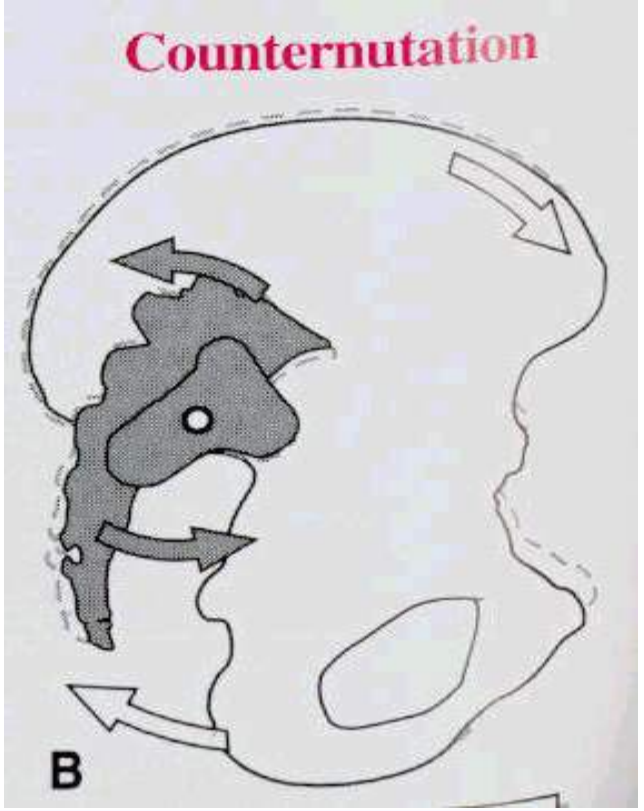

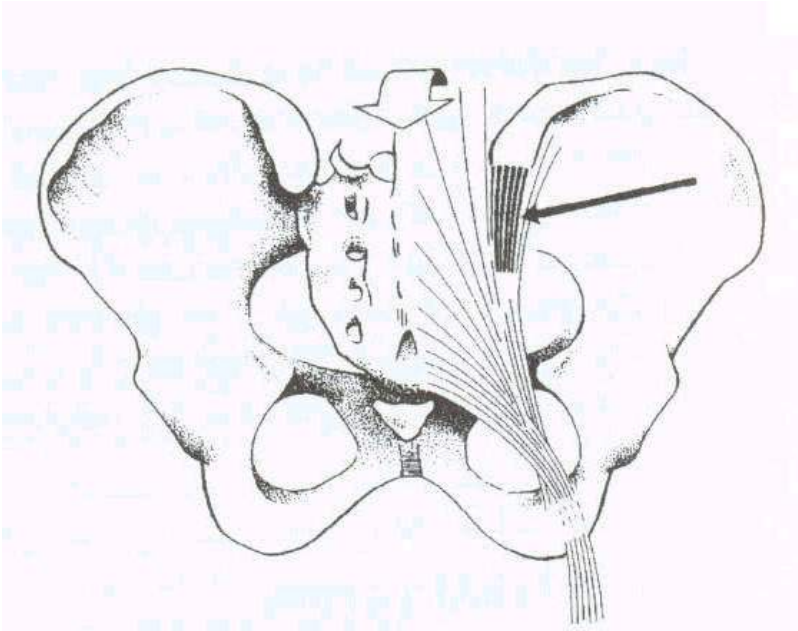

POSTURE

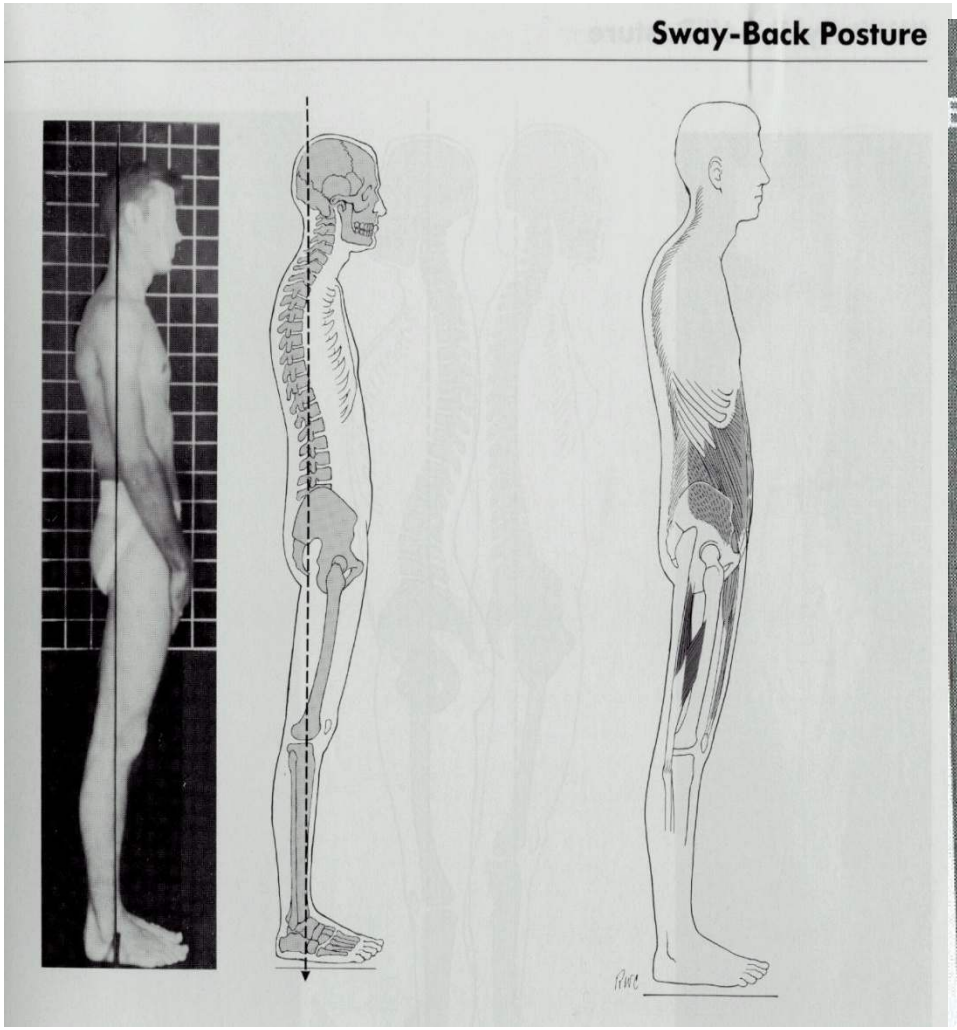
Sway-Back Posture

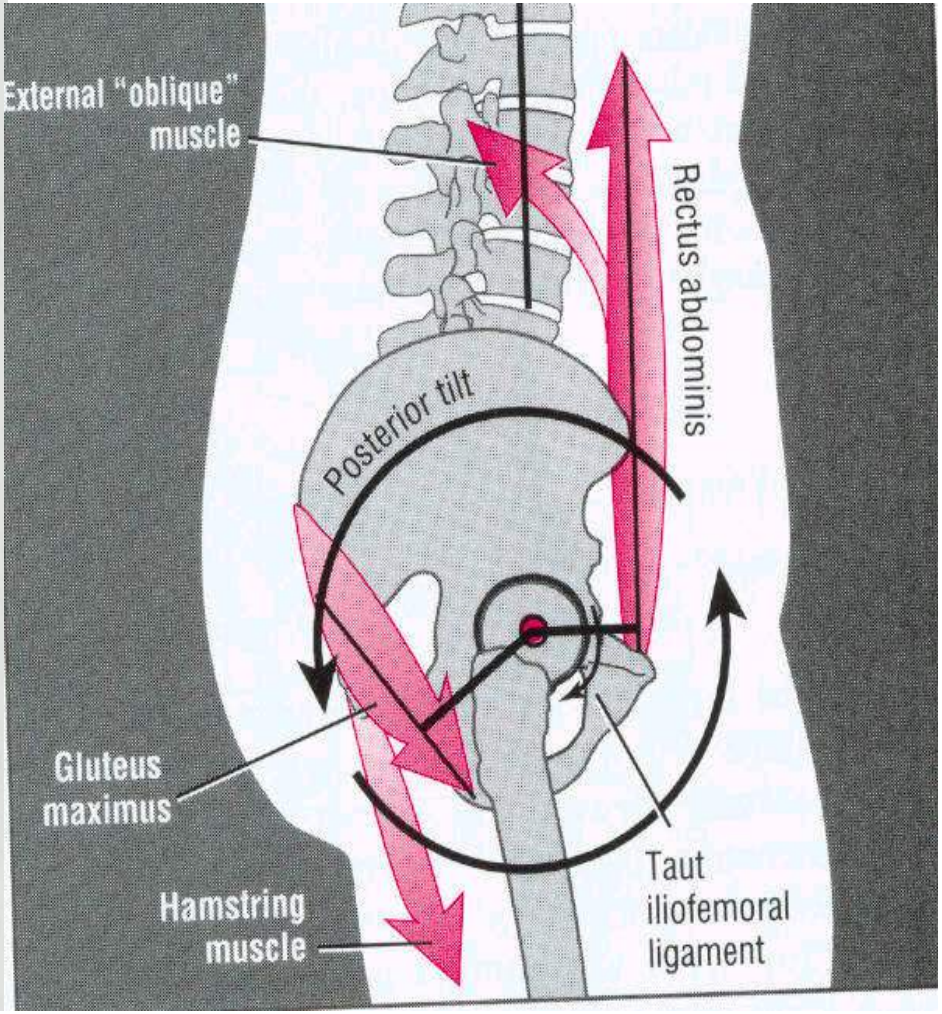
External "oblique" muscle
Rectus abdominis
Posterior tilt
Gluteus maximus
Hamstring muscle
Taut iliofemoral ligament

POSTURE

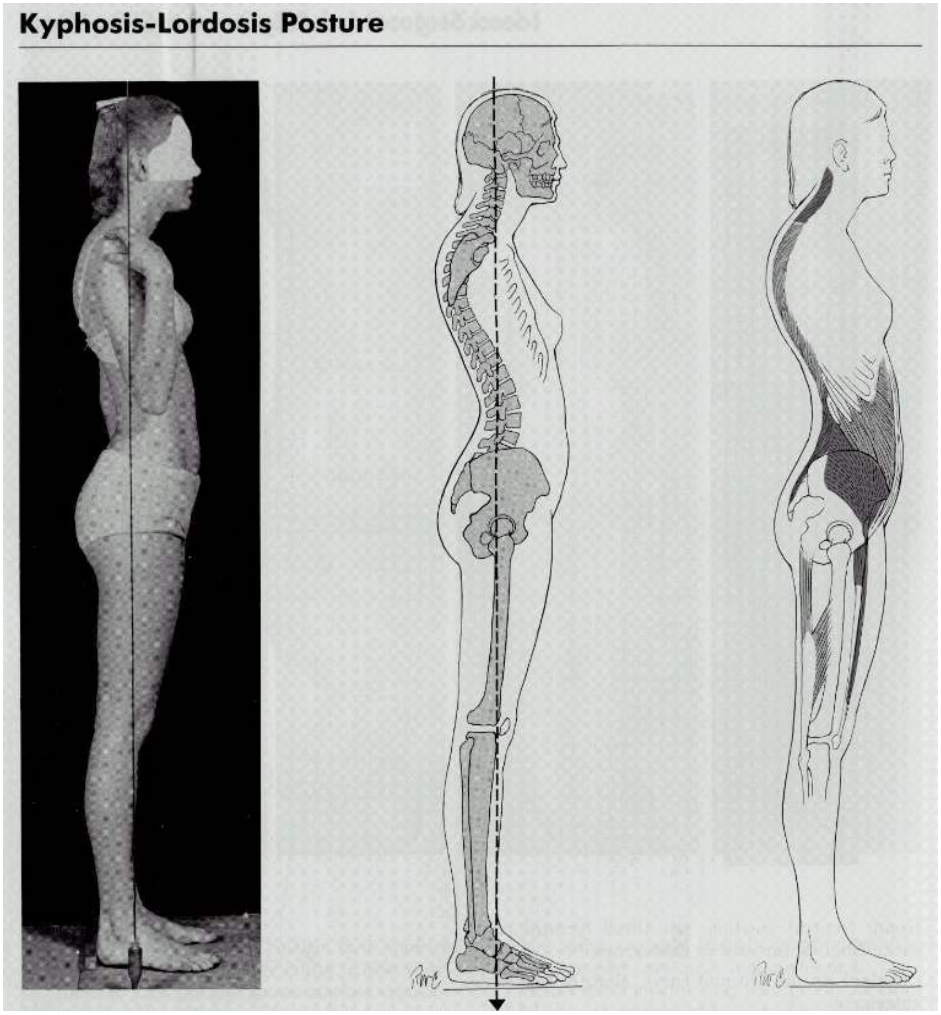
Kyphosis-Lordosis Posture

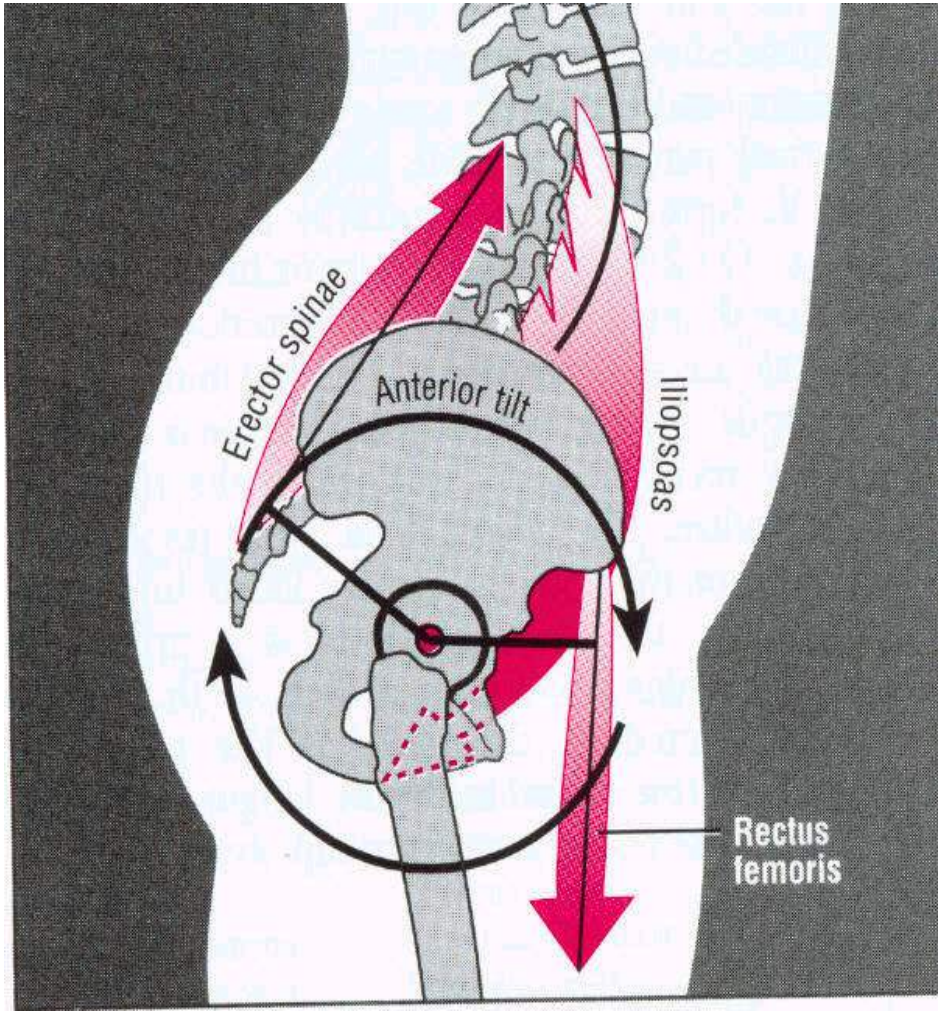
Erector spinae
Anterior tilt
Iliopsoas
Rectus femoris

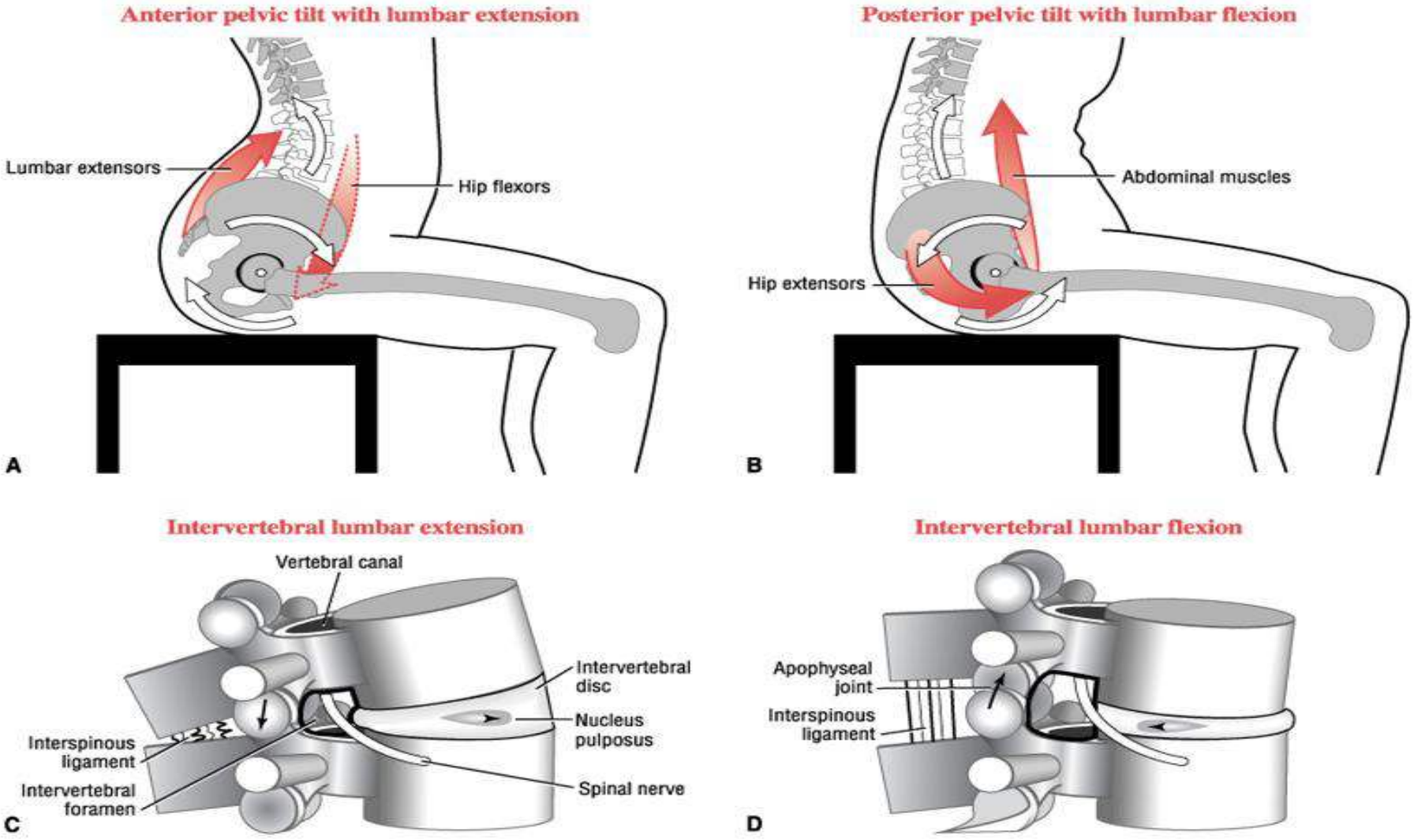
Anterior pelvic tilt with lumbar extension
Lumbar extensors
Hip flexors
A
Posterior pelvic tilt with lumbar flexion
Abdominal muscles
Hip extensors
B
Intervertebral lumbar extension
Vertebral canal
Intervertebral disc
Nucleus pulposus
Interspinous ligament
Intervertebral foramen
Spinal nerve
C
Intervertebral lumbar flexion
Apophyseal joint
Interspinous ligament
D



This is doctor and patient placement for the seated palpation for nutation. The doctor's hand is on the upper part of the sacrum and the doctor brings the patient into extension while palpating in a P-A direction.

This is the doctor and patient placement to motion palpate the sacrum in counternutation. The patient is flexed forward and the doctor palpates from P-A and S-I on the lower part of the sacrum.

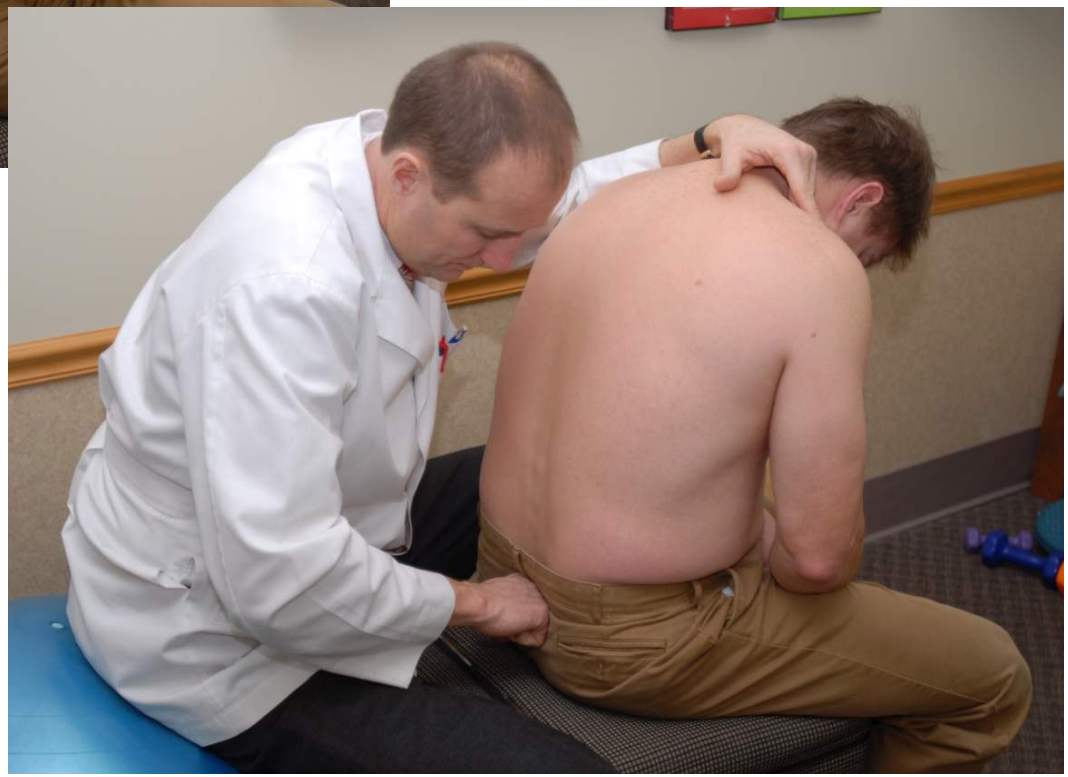

JOINT PLAYING COUNTER-NUTATION AND NUTATION

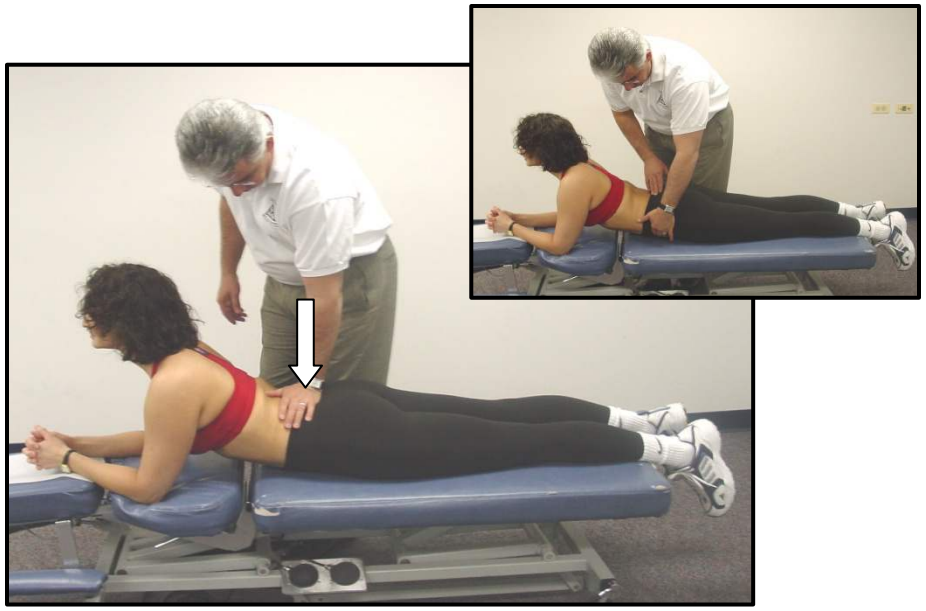

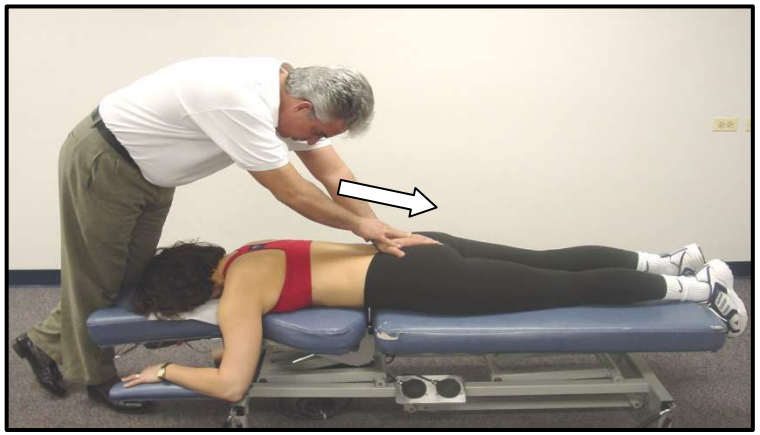

Check-List

- <u>SIDE POSTURE:</u>
- Kick-Knee Bent with lots of dorsi-flexion above the contact.
- Drop- most weight on lead leg oblique entry.
- Pack in the compression then RELAX.
- Drop depends on height.



Dropping VS. Kicking

- Drop mechanics
  - 45 degrees & **lots of <u>dorsi-flexion!</u>**
  - Roll patient into your home.
  - GET CLOSE (nose to the contact) !
  - Add contact, brings forces together…DROP.
    - Keep rounded
    - Keep drop short and quick
    - NO PRE-LOAD
    - No Torque of the torso

- Kick Mechanics:

  -90 degrees to patient

  -LOTS OF DORSI-FLEXION!

  -Patient stays neutral

  -NO PRELOAD

  -Kick & Pull happens together (like snapping fingers).

  Pull is into your body

  Kick like a soccer ball is under the table

  Quick and short

Don’t confuse moving fast with making jerky movements.”
Rob Lawerence RKC Sr.

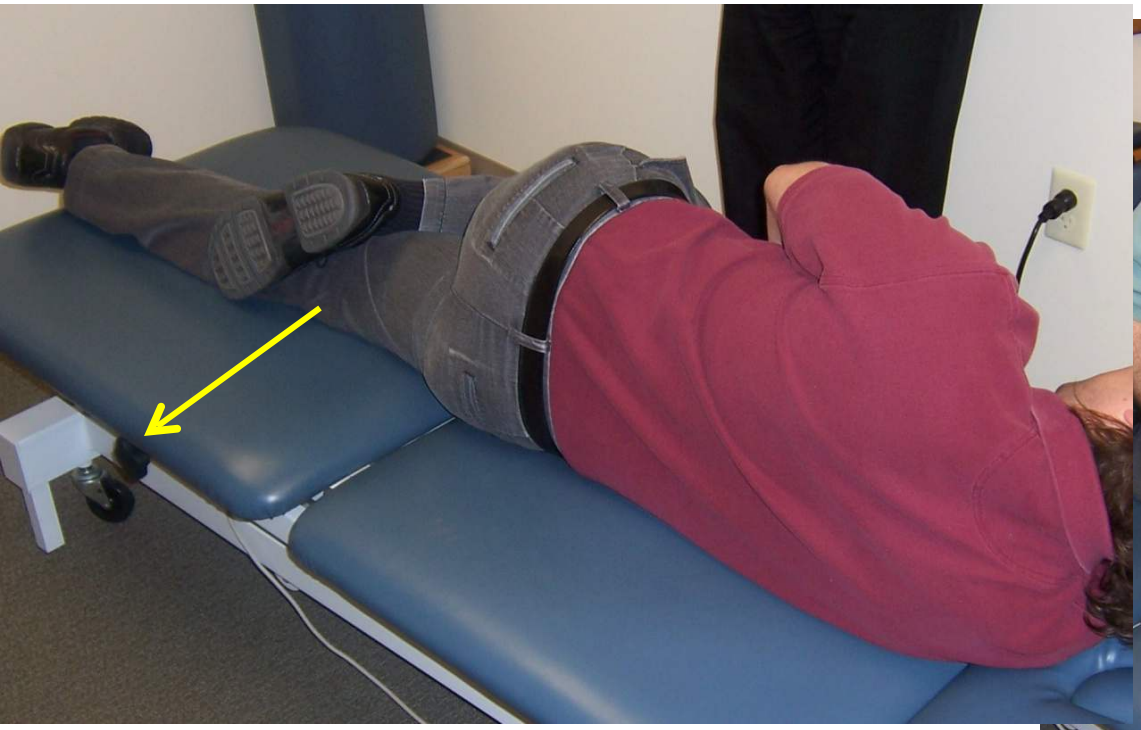

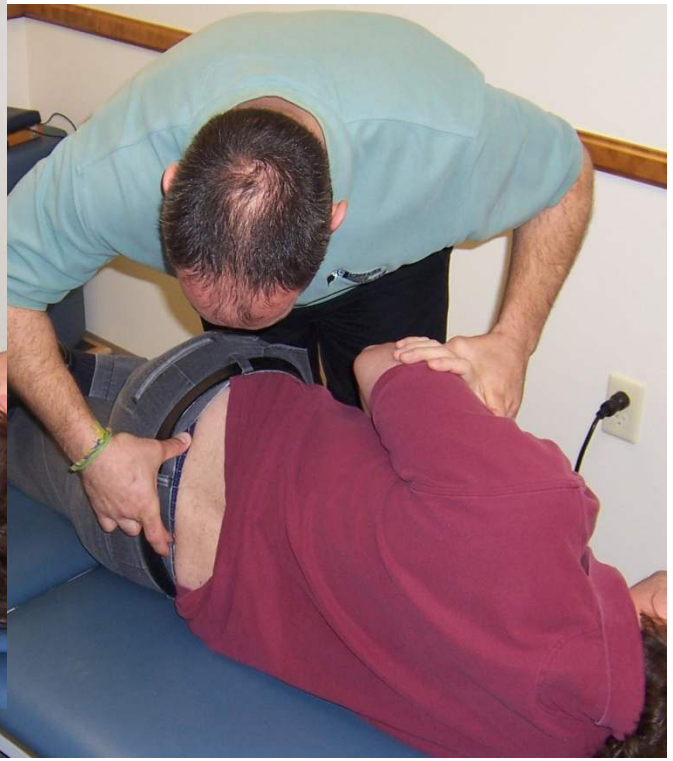

Pt position is neutral with slight extension of the bottom leg.
Contact is broad hypothenar/thenar contact b/w the PSIS.
Compress contact and stabilizing arm together and drop.

Sacral Nutation- Kick



-Same set-up rules for drop

-Kick and push happen split seconds apart.



Counter-Nutation-Palpation

- **Most beginners finish this adjustment where experienced adjusters start it. “Effortless power vs. Powerful effort”**
- Palpate the L/S junction with your fingers and flex the top leg until SP flexion stops. Then add the contact. Utilize your back leg to keep the joints at the restricted point of the axis…Drop with speed.





Counternutation



COUNTERNUTATION DROP







- Flex the bottom leg.
- Contact: Apex of the sacrum with the elbow out. 1.
- Bring the elbow into your side thus adding counternutation tension. 2. → Drop
- OR Use the forearm contact and align more parallel. “Pee-wee Herman”. 3.





- Broad Forearm contact

-Stay close

-Create some CN with tissue pull.

-SLAP AND GO

Counter-nutation: kick/pull (slap)



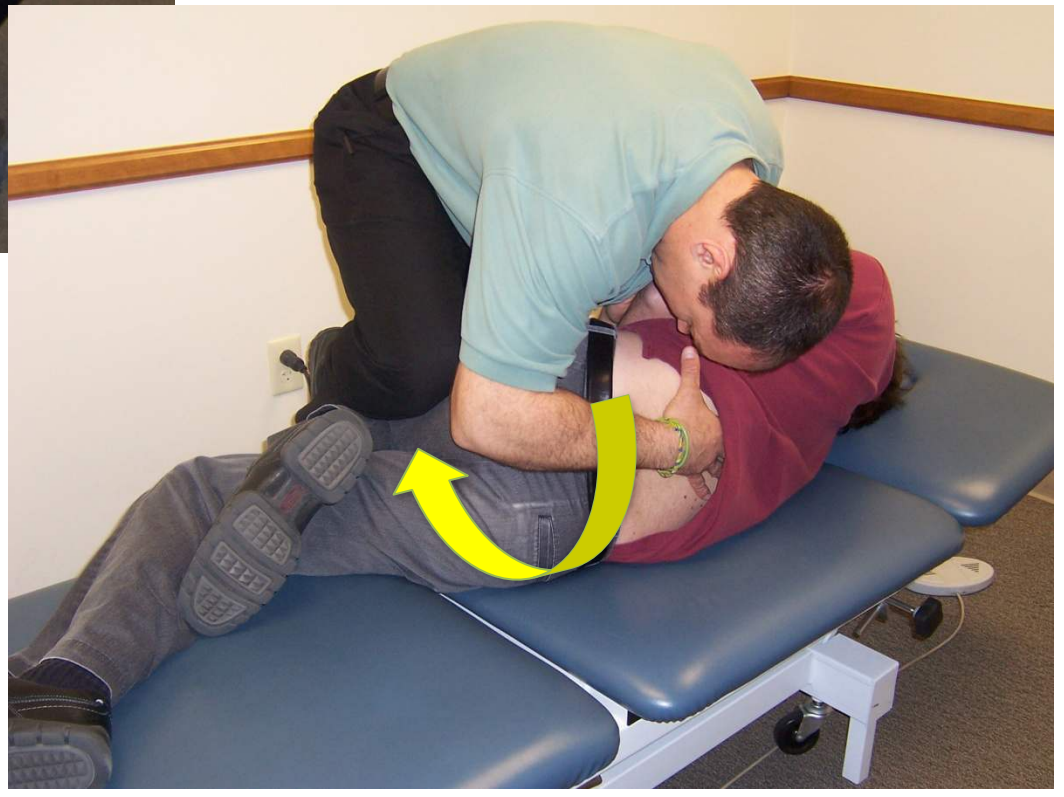

-90 with lots of dorsiflexion.

-Kick leg knee in pocket.

-Adduct the kick leg slightly to create a CN force.

-Envision pulling your elbow into your side as fast as you can.

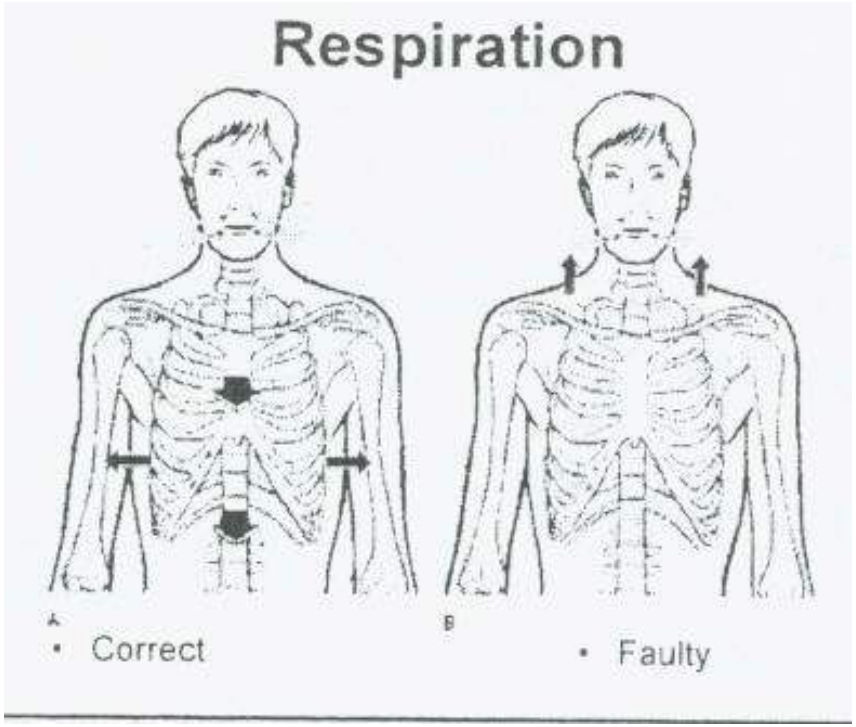
Respiration
A
• Correct
B
• Faulty

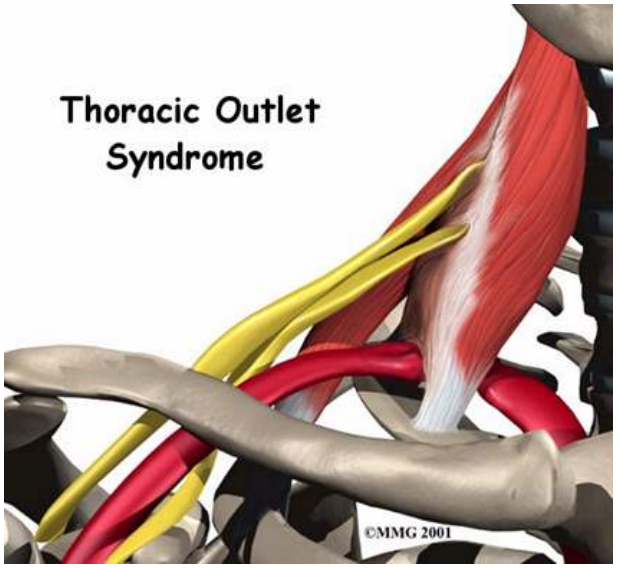
Thoracic Outlet Syndrome
©MMG 2001

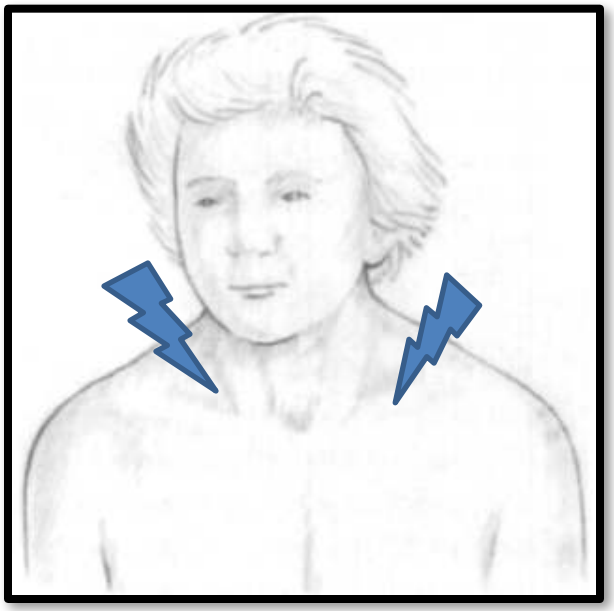


Diaphragm
looking up into the ribcage
central tendon
crura
quadratus lumb.
psoas major



Our Field:
"We are after function, not cosmetics"

...Karel Lewit



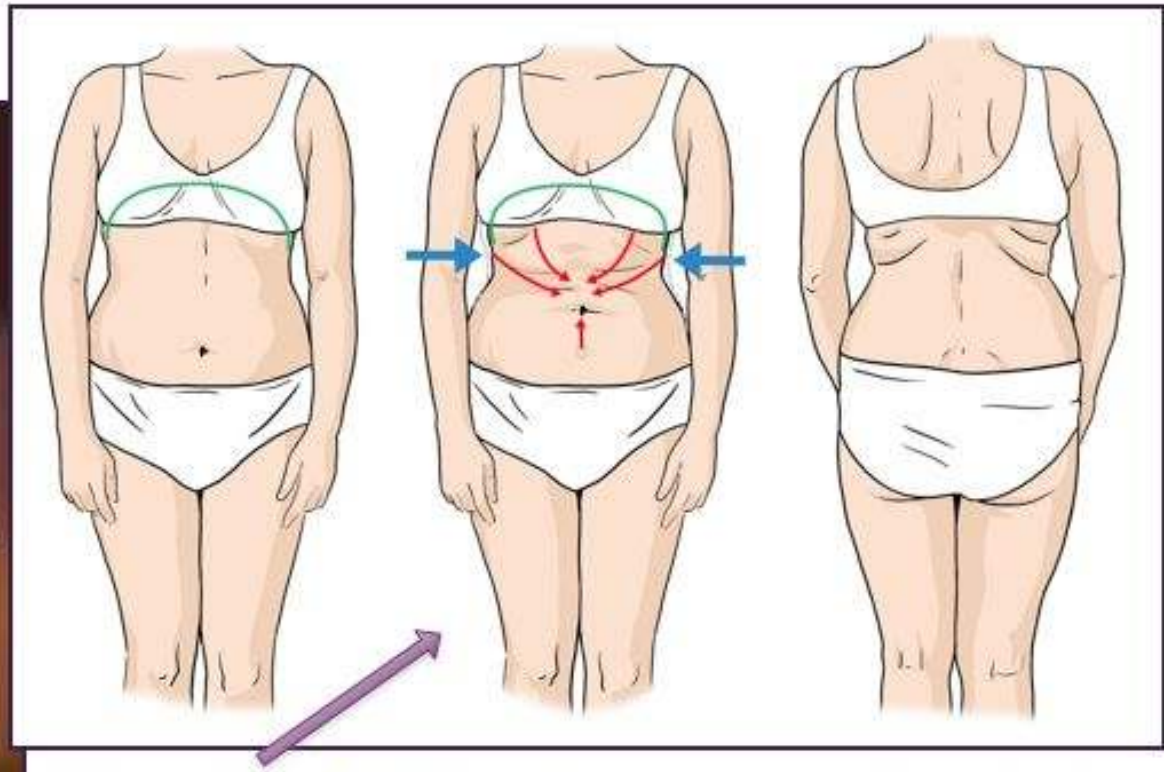

"Hour glass" clinical picture according to Kolar

Altered Breathing Patterns and Chronic Low Back Pain

Approximately 60 % of CLBP patients demonstrate altered motor control strategies, specifically relating to breathing patterns, during simple motor control tasks that challenge lumbar spine stabilization

Rousel, N. European Spine Journal; 2011

“Abdominal Canister”

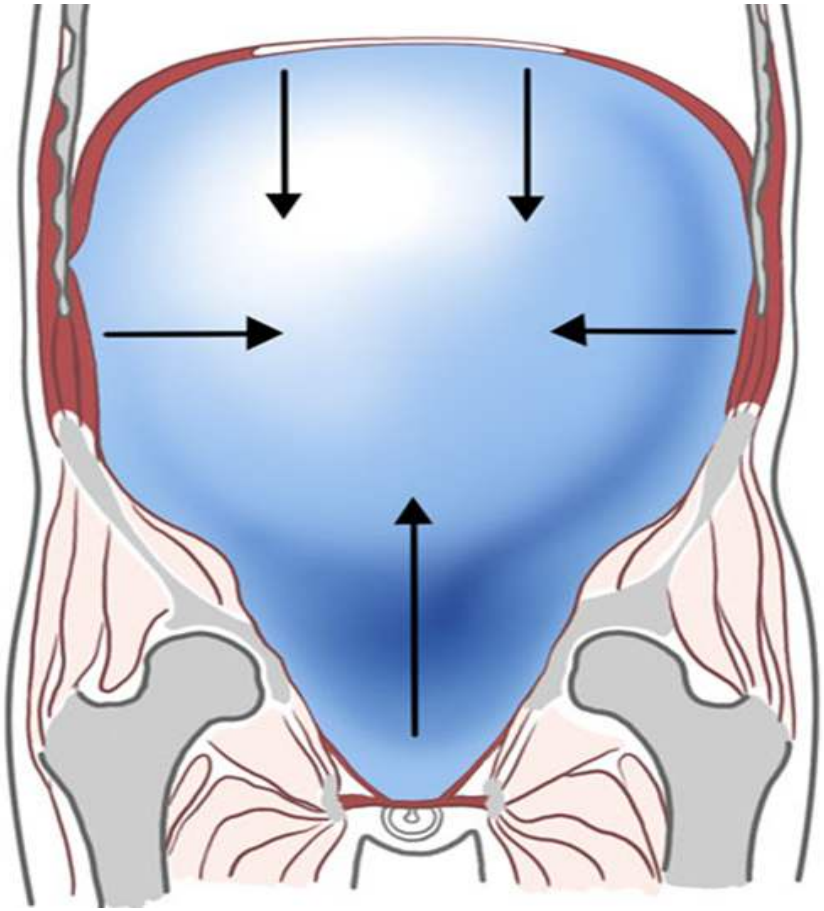

- The contribution of TrA to lumbopelvic stability involves increased IAP and fascial tension
- Changes in these parameters require co-activation of the diaphragm and pelvic floor
- Activity of these muscles occurs in conjuction with TrA during arm movements
- Hodges, 1999

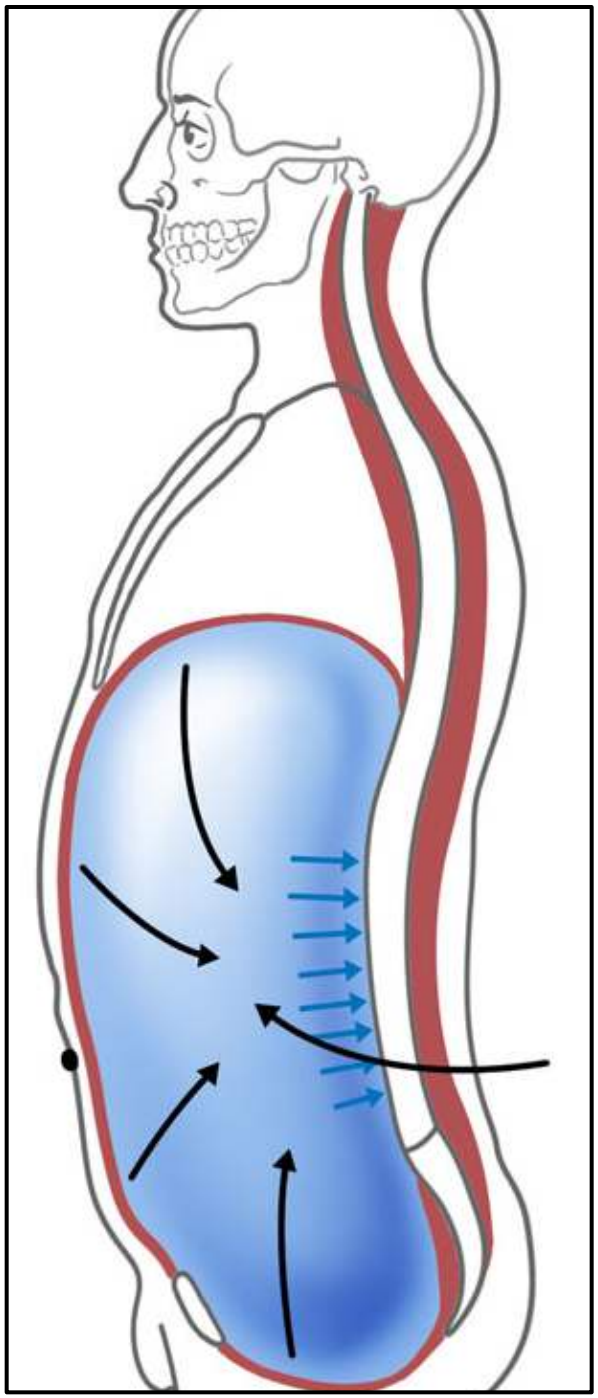

The low back is stabilized via intra-abdominal pressure

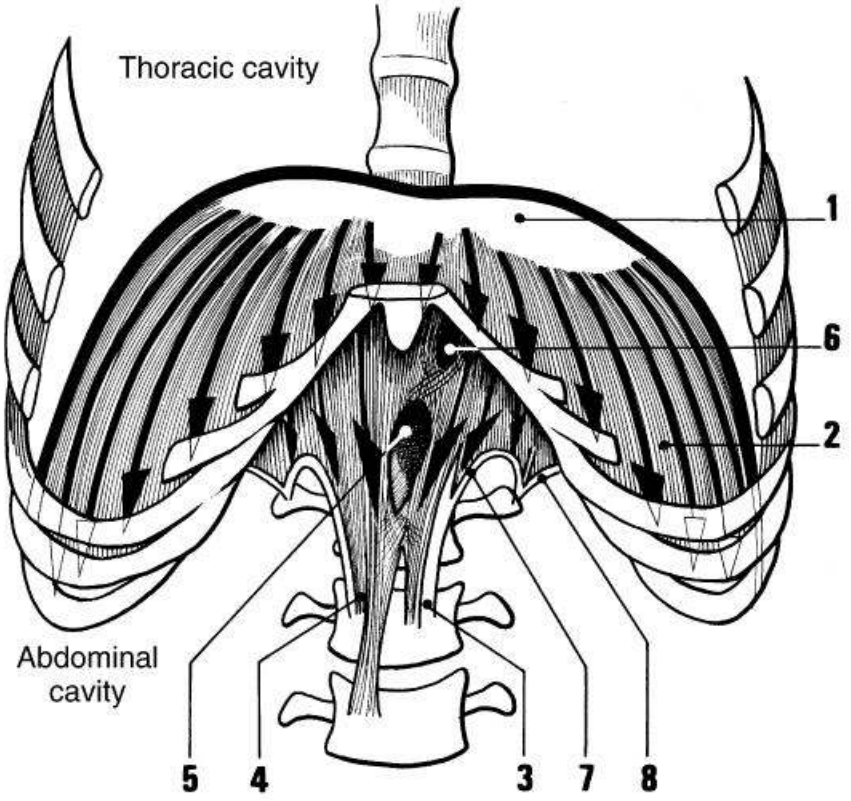

Testing the Diaphragm -Kolar/Prague School

- Symmetrical activation against the therapists fingers
- Expansion of the lower ribs laterally.
- Widening of the intercostal spaces.
- Ribs stay in the same plane.
  - No superior movement of the ribs.

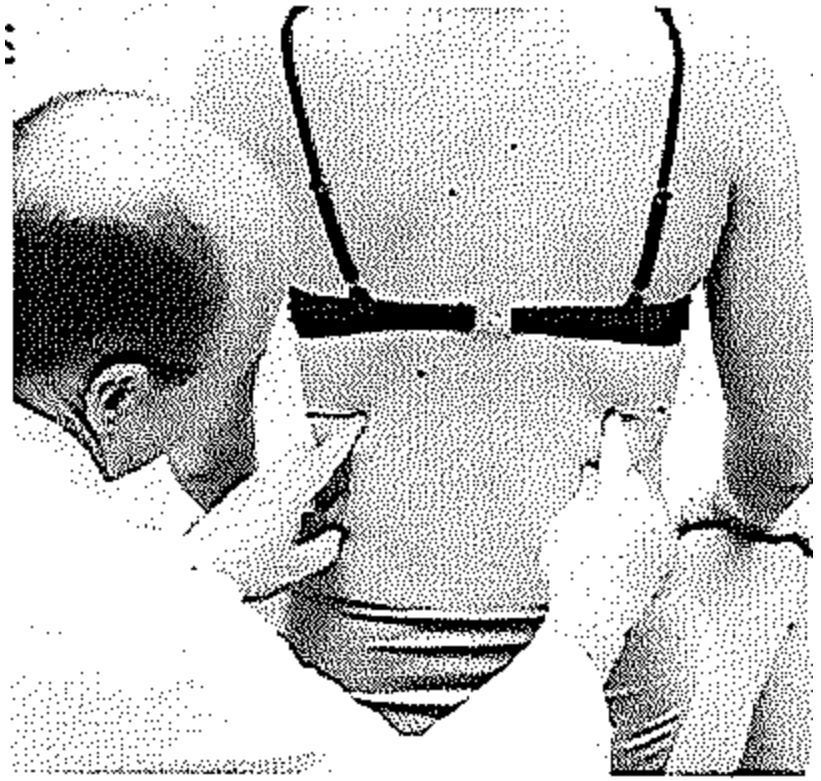

RESPIRATION ASSESSMENT SYSTEM

- Palpate the intercostal spaces of T11-12 & ask the patient to breathe normally →
- LOOK at where respiration is happening (don't stop to take notes) →
- Palpate the upper traps/ lev. Scap and scalenes while patient is breathing. →
- Palpate the lumbar spine and abdomen→
- NOW cue the patient to see if they can change an incorrect pattern to a correct one. →
- Yes= Real world application NO= RETRAINING

Respiration Retraining

- **Supine is usually best to start.** **<u>Retraining the 360 degree hoop in steps.</u>**
- **Utilize visual and palpable cues.**
- **Constant bio-feed back is essential.**

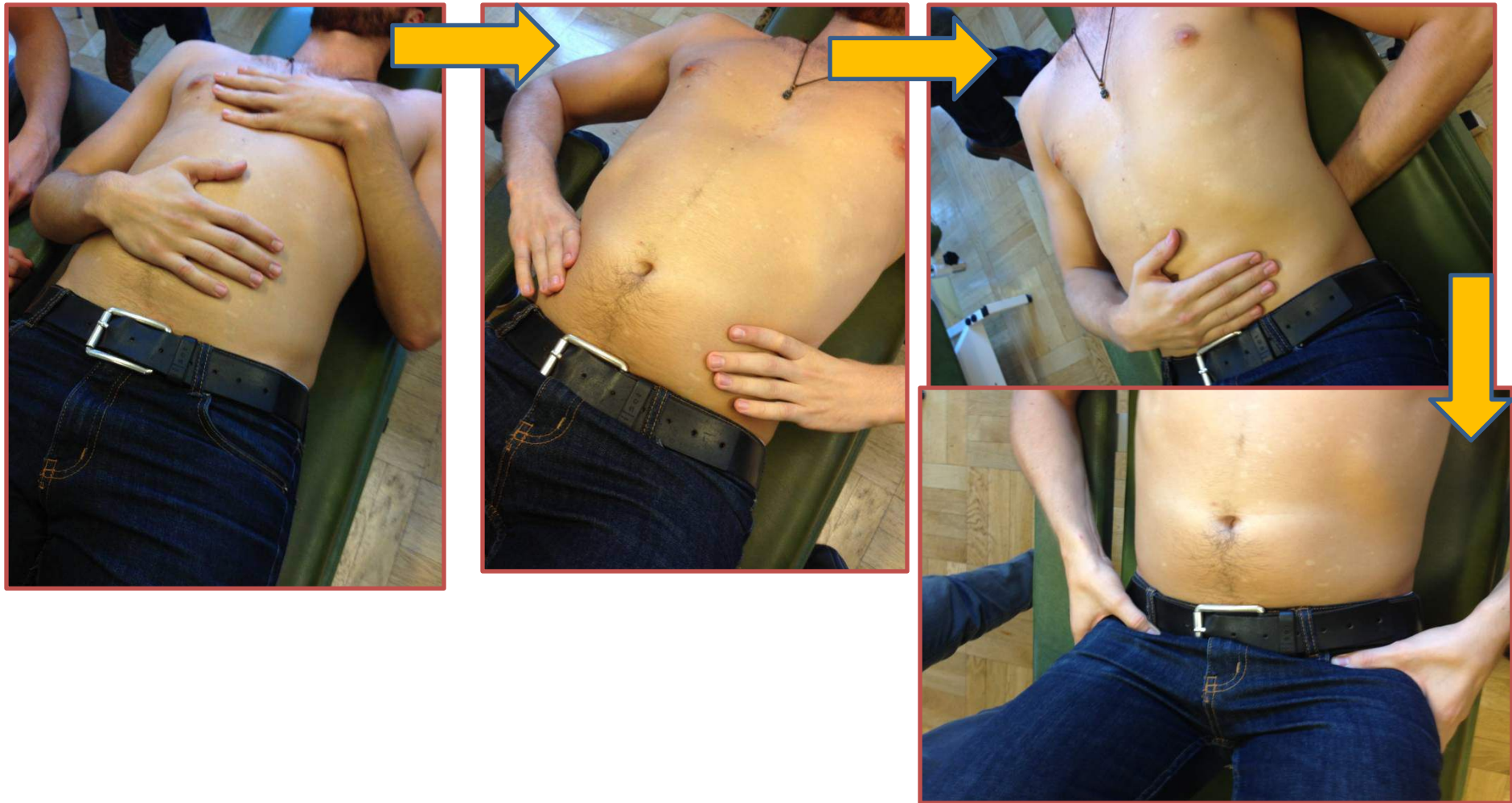

Cervical Spine Assessment

- Seated:
  - Palpation
  - Respiration
  - ROM with/ Palpation
  - Seated End-Range loading
  - Target test (WAD)
  - Reflexes
  - TOS/1st Rib



Cervical Spine-Seated

- **Neck Flexion Test:** N – ABN
- Chin Thrust – Endurance_____
- **End-range Loading:** Centralization Y / N WORSE
- **Shoulder Abduction Test:**
- L N – ABN_____
- R N – ABN_____
- **Shoulder Flexion:** Controlled: Y / N RT Fail / Lt Fail
- **Facet shear test: Level_____ Side: RT / LT**
- **Respiration:** Inspiratory breathing: Y / N
- Uncontrolled even with cueing Lt / Rt
- Frontal Plane breathing : Y / N with cueing: Y / N
- Myofascial restriction limiting frontal plane: Lt / RT
- Joint restriction limiting sagittal plane: Upper T-spine/ TL / CT
- **Target test: 10 - 8 - 6 (repeat 3 times)**
- **Joint Palpation:**

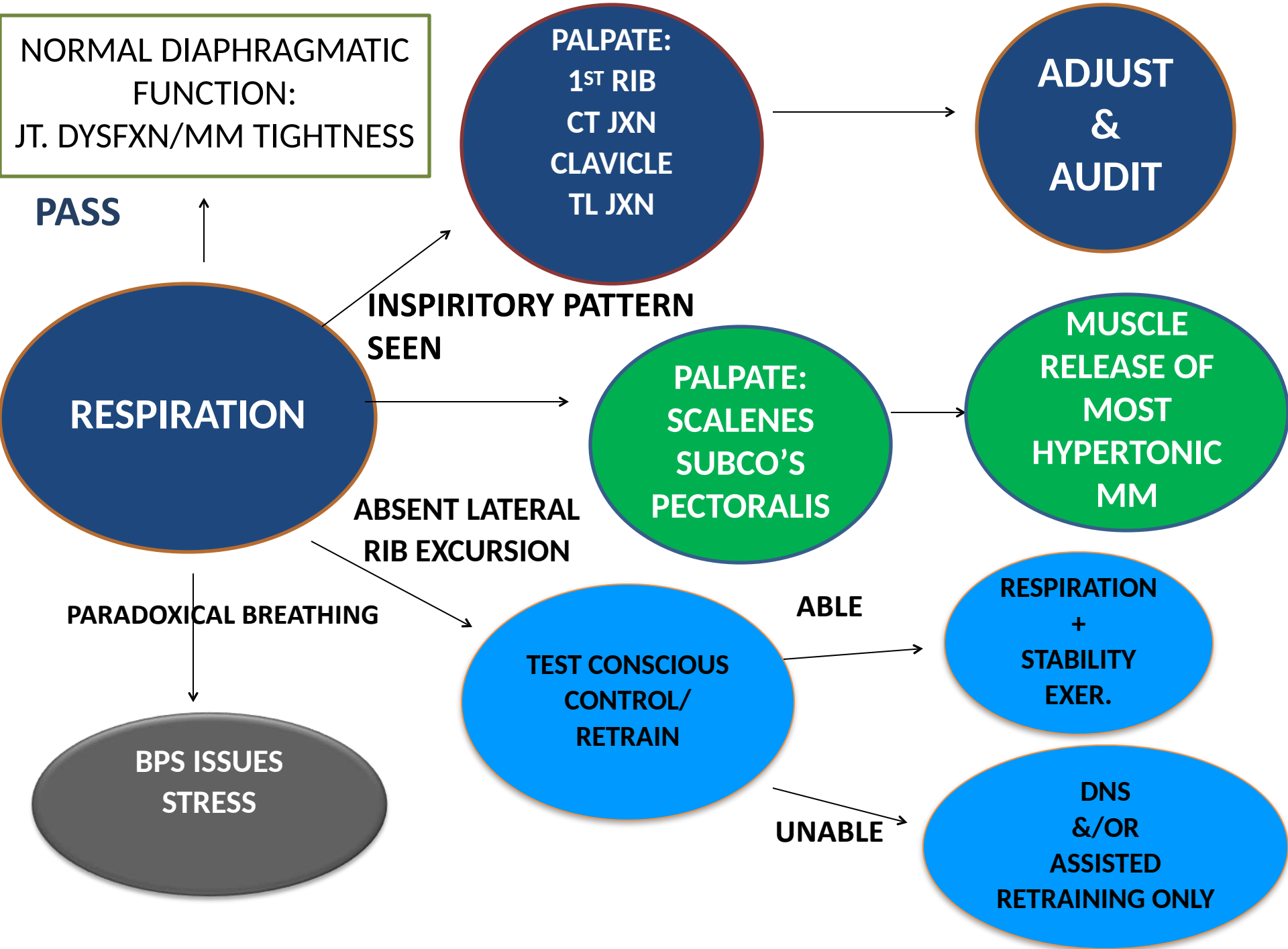
NORMAL DIAPHRAGMATIC FUNCTION:
JT. DYSFXN/MM TIGHTNESS
PASS
PALPATE:
1ST RIB
CT JXN
CLAVICLE
TL JXN
ADJUST
&
AUDIT
RESPIRATION
INSPIRITORY PATTERN SEEN
PALPATE:
SCALENES
SUBCO'S
PECTORALIS
MUSCLE RELEASE OF MOST HYPERTONIC MM
ABSENT LATERAL RIB EXCURSION
PARADOXICAL BREATHING
BPS ISSUES
STRESS
TEST CONSCIOUS CONTROL/ RETRAIN
ABLE
RESPIRATION + STABILITY EXER.
UNABLE
DNS &/OR ASSISTED RETRAINING ONLY

CERVICAL SPINE-SUPINE

- Palpations:
  - Upper cervical spine
  - 1st rib
  - Glenohumeral joint
  - Scalenes, Suboccipitals, Subscapularis, Pec Minor
- End-range loading
- Neural Tension
  - Neural tension with isometric contractions.
- Int/External Shoulder rotation
- TMJ assessment

Cervical Radiculopathy

- Look for positive doorbell sign
- Adjust ipsi-lateral coupled motion.
- Typically flexion is needed in the C4-6 segments and extension below that.
- McKenzie techniques are very helpful in treating these conditions along with neurodynamics.

Cervical Radiculopathy Screen and Mobilization





- Pt. shoulders at the end of the table.
- Distract→Lightly retract→ extend to tolerance.
- Repeat until parasthesia is centralized.



Cervical Spine Mechanics

- Protraction (FHP) =
  - Upper t-spine & mid/lower c-spine→ FLEXION
  - Upper C-spine → EXTENSION
  - Distortion of muscular forces
- Retraction (chin tuck/ nodding “yes”) =
  - Upper t-spine & mid/lower c-spine→ EXTENSION
  - Upper C-spine → FLEXION
  - Approximation and efficient muscular interaction…IF ITS SHARED WITH T-SPINE!

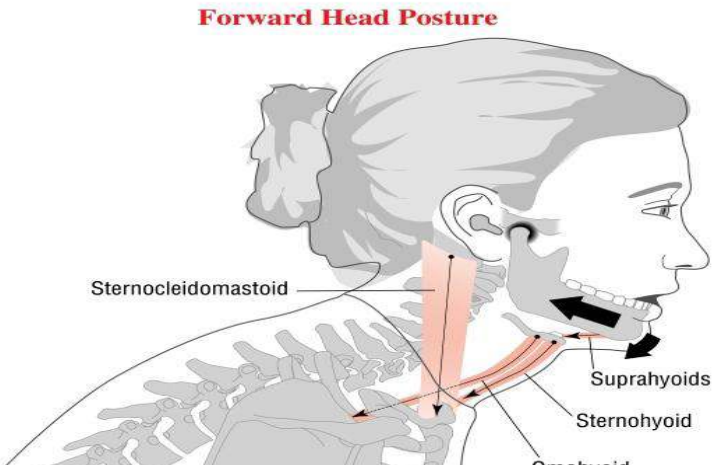

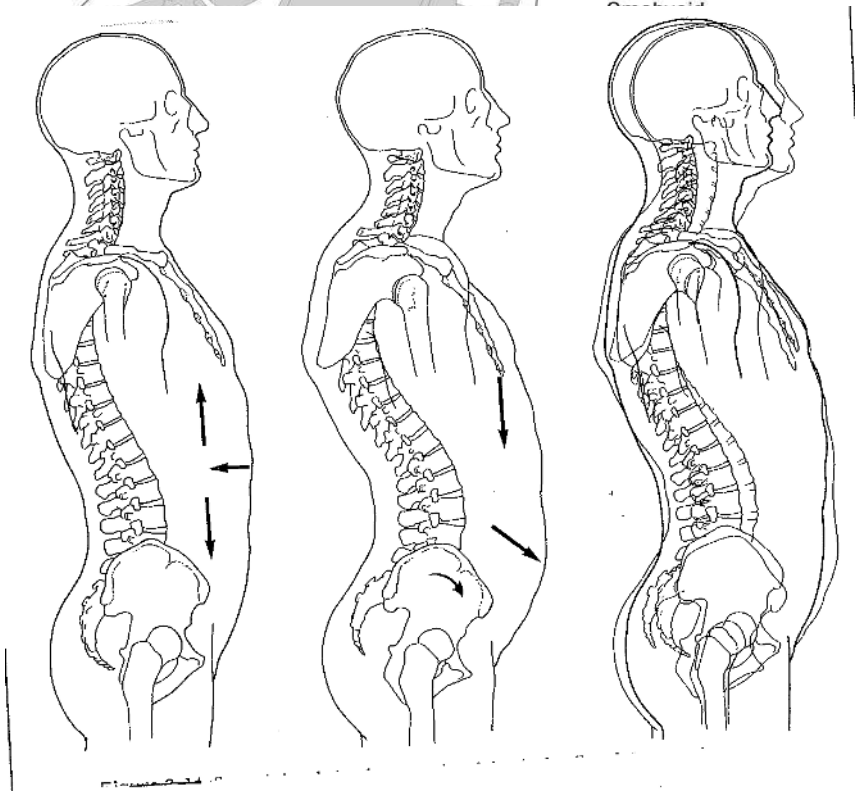

Biomechanical Principles of the Cervical Spine

- ***Important biomechanical principles***

  - All joints rotate & translate around 3 axes (X,Y,Z)
  - Upper c-spine predominates rotation
  - The lower c-spine is built to BLOCK ROTATION. (Porterfield, Derosa)

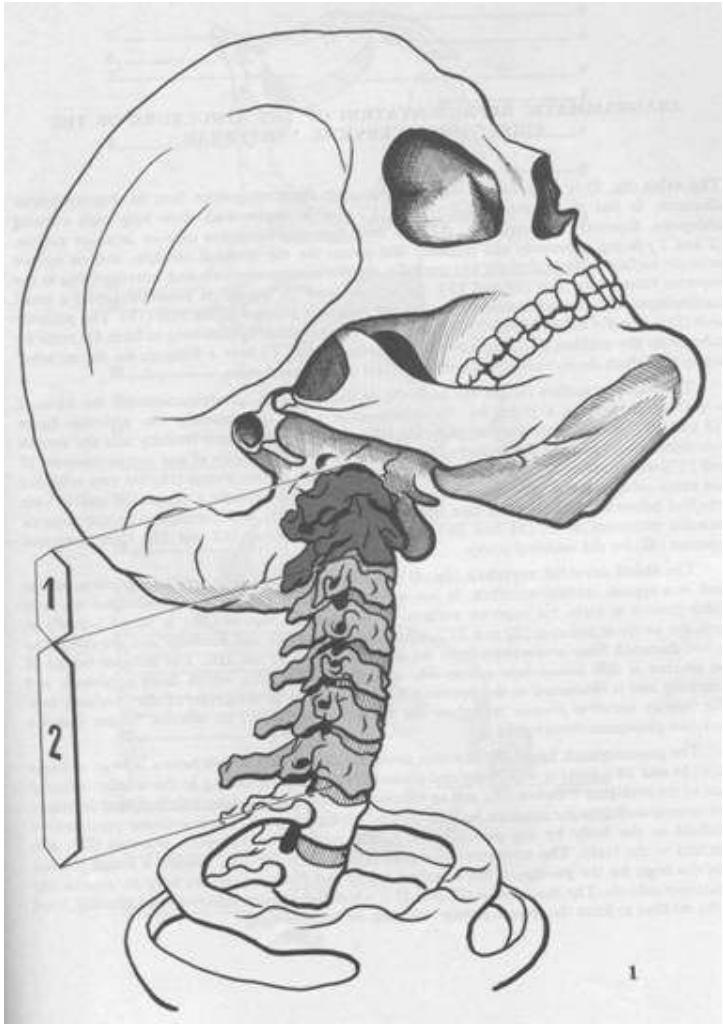

Craniocervical axial rotation

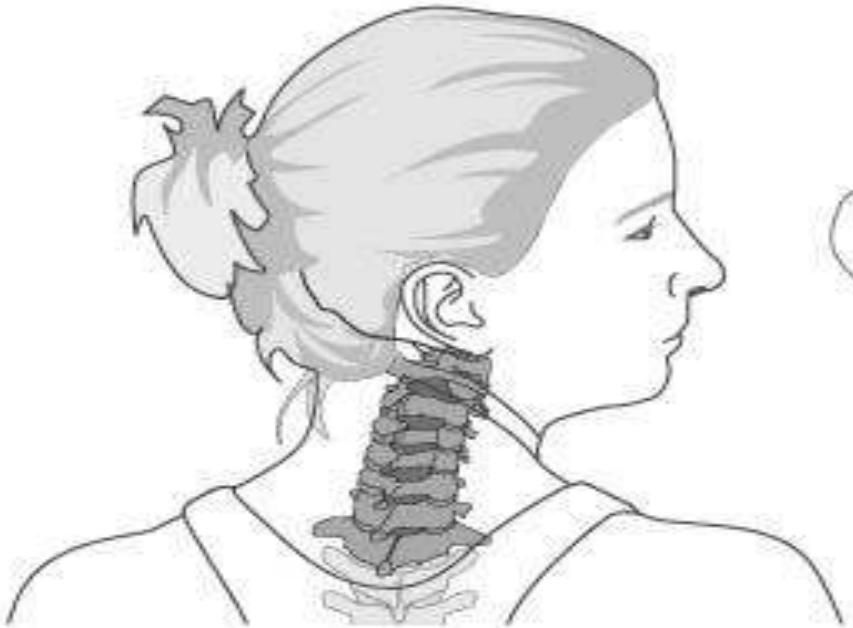

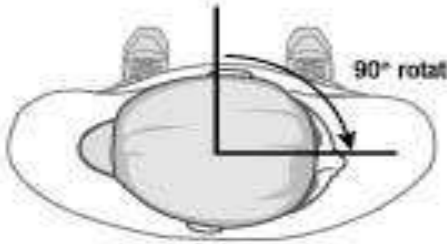

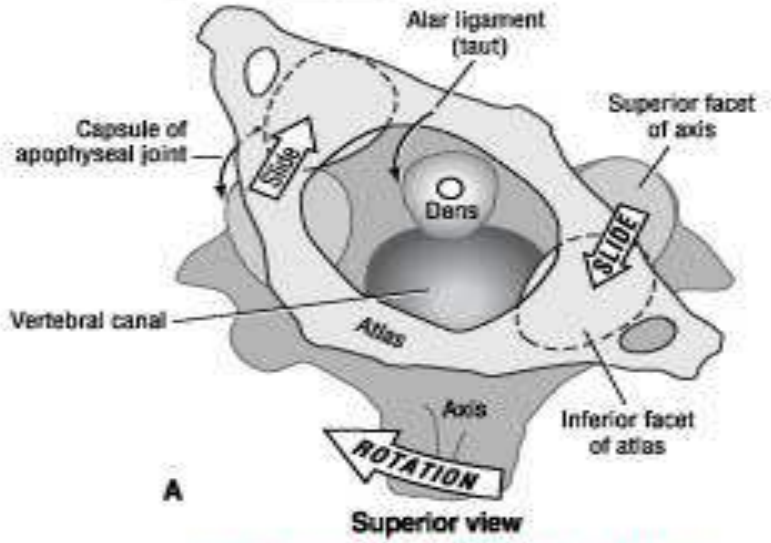

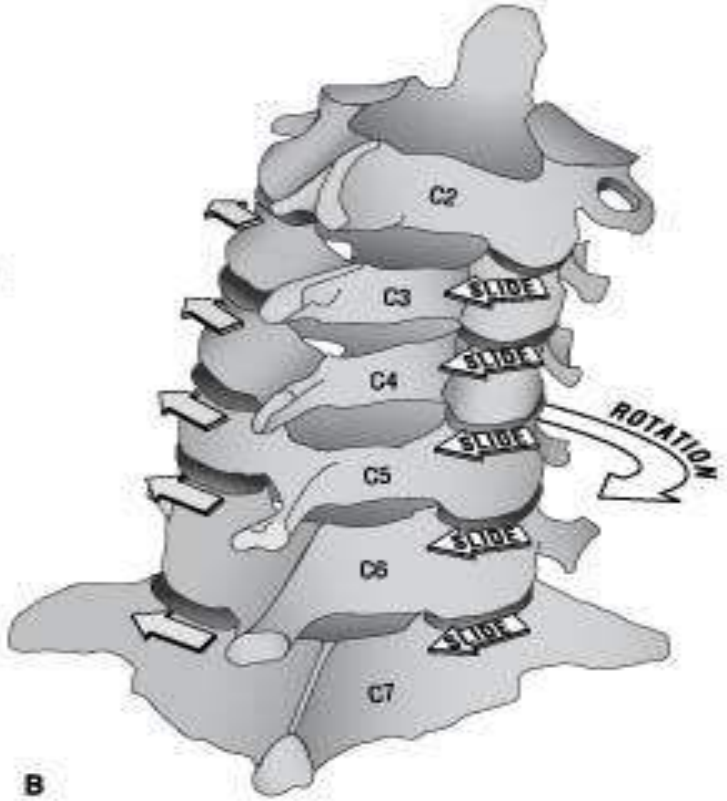

Atlanto-axial joint complex (C1–C2)

Intracervical region (C2–C7)

Cervical Spine-lateral flexion

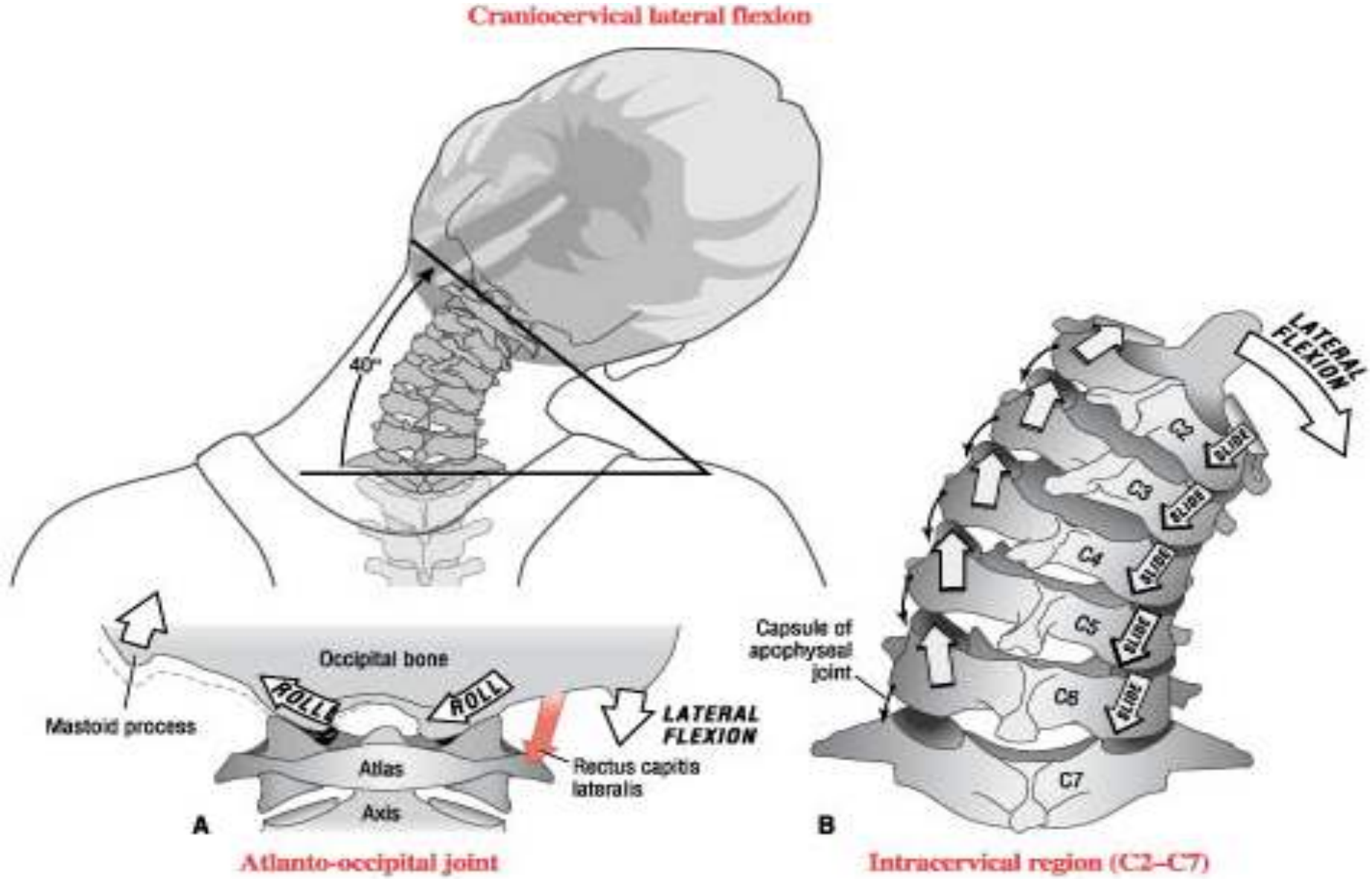

Seated Adjusting

1. Xyphoid height or lower (where are you adjusting? i.e. CT is lower)
2. Contact is NOT rigid…just lay it down.
3. Stabilizing hand is actually a traction hand & plays a role in the adjustment; it's not passive.
4. Stay close and cover large amounts of surface area. You should have at least 4-5 points of support (stabilizing hand & body: 3 thrust hand: 2).
5. RELAX/ FEEL THE RESTRICTION under the contact)/ PULSE through the joint.

Seated Adjusting

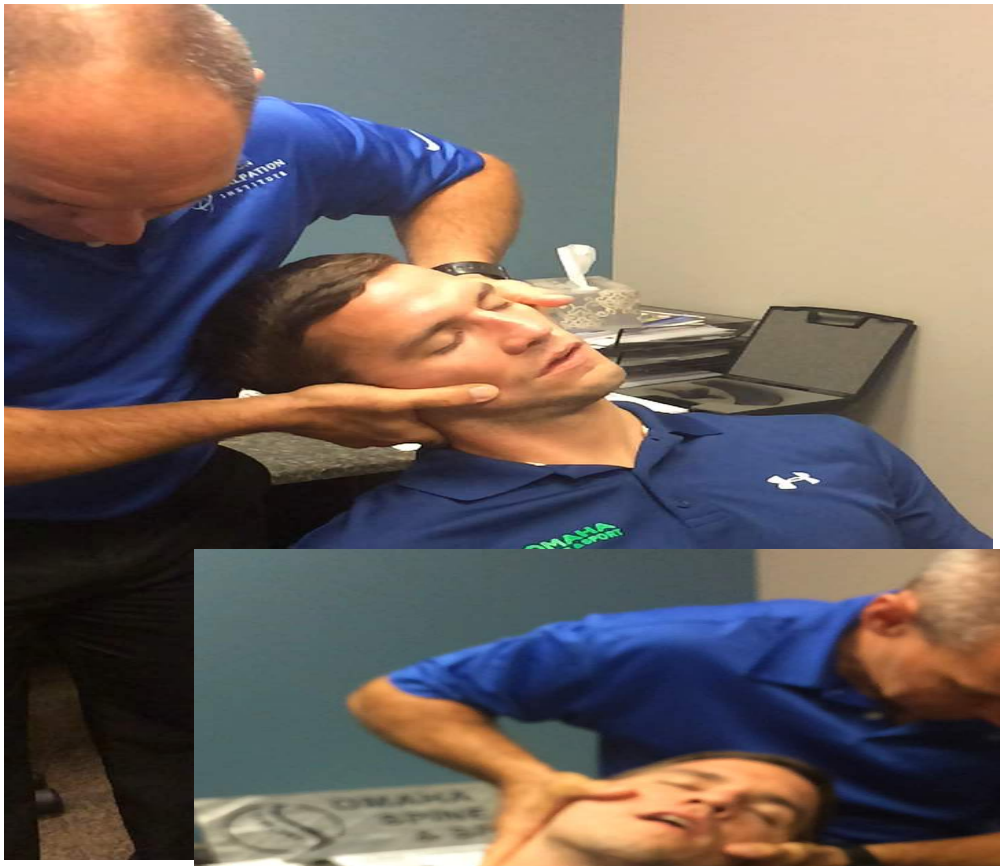



Hands are wide and SOFT.

Hands work synergistically

Soft contacts=RELAXED

RELAXED means TONS of potential energy and tissue sense

RELAXED & CLOSE=FAST!!

STABLE=IAP whenever you need it.

Upper Thoracic / CT Palpation





- Extension palpation:
  - The doctor brings the head further into extension pushing P-A for joint play using the doctor's thumb.
  - *Clinical note:* FHP is common in our society and the CT spine is often restricted in extension. You must clear this restriction before beginning rehabilitation.

- Rotation palpation

•The patient's head is rotated to the right and the doctor is palpating on the left side of the T1/2 facet and joint playing P-A and in a rotary manner.

CT Lateral Flexion Palpation



This is doctor and patient positioning for left lateral flexion at T1. The doctor's thumb is placed against the T1 spinous process. The patient's head is laterally flexed to the left with the doctor joint playing from left to right against the spinous process for relative lateral flexion. This is done bilaterally.

CT Junction Lateral Flexion

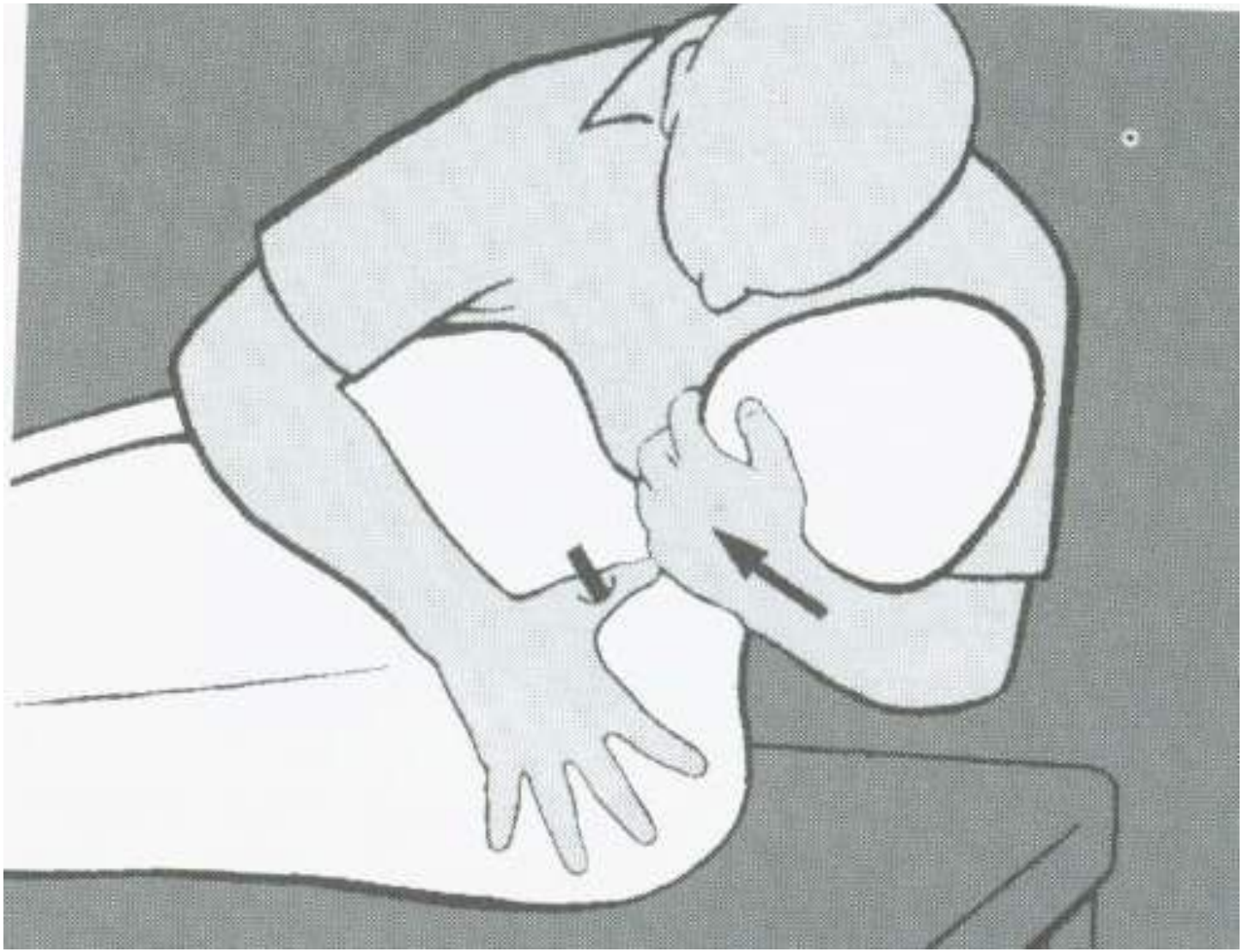

Cervicothoracic segment C5 to T3: translatoric joint play

test



Figure 26 – C5-T3

Cervicothoracic segment: flexion and extension

test and stretch mobilization

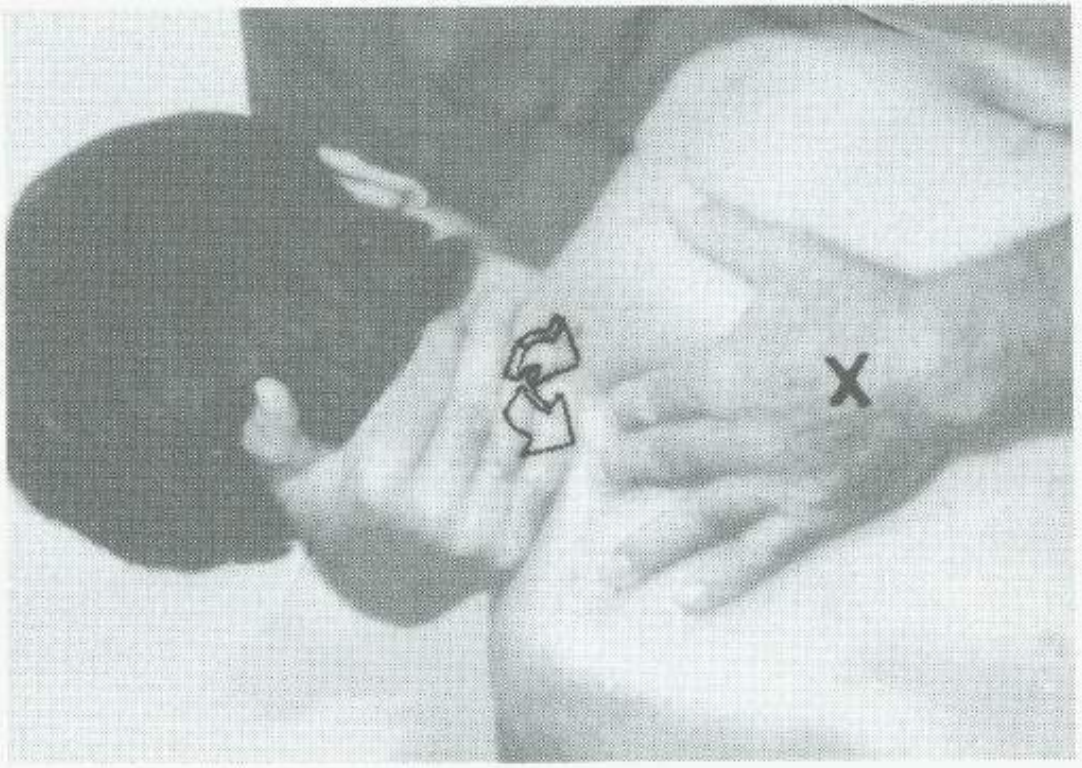

Figure 27



- Create a box with your arms.
- Move your body inside the box by "taking a bow if you're shorter or bending at the knee if you're taller.
- The off hand creates TRACTION (so important)!
- Relax/waggle (possibly lean in) → Thrust/impulse=THRIMPULSE
- Patient's head can be stabilized with chest or upper arm.

✓ Your midline is outside shoulder ** Your wrist is neutral to extended.
✓ Your outside knee is NOT diving inside **Your shoulders are relaxed
✓ You are bent NOT rotating around. ** Where is your weight? 80/20.
✓ Your contact is light and you can feel the motor segment underneath.
✓ YOU ARE RELAXED—Where is the tone?
✓ If you had a line drawn down your forearm where is it going?

Perfect Practice







20%



80%



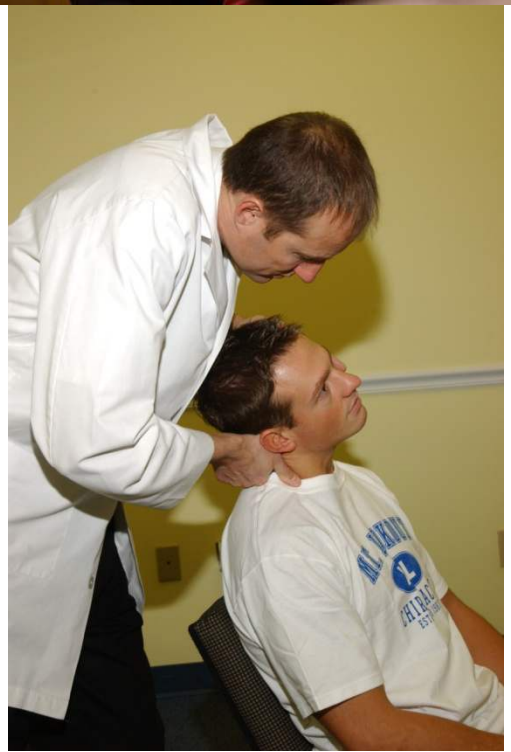

CT Extension-Seated

- Xyphoid Height
- Contact is light! Backed up Index finger in the spinolamniar junction.
- Retract→Distract (up)→Step Step Bow →Retract and Extend more if you need to.
- Move your body inside the box by “taking a bow if you’re shorter or bending at the knee if you’re taller.
- The off hand creates TRACTION (so important)!
- Relax/waggle (possibly lean in) → Thrust/ impulse=THRIMPULSE
- Patient’s head can be stabilized with chest or upper arm.

The 3 T's of Supine CT Extension







1. Extend the headpiece slightly
2. Patient position is supine with the ipsi-lateral arm UNDERNEATH the contralateral.
3. Start a soft-close fist or open hand up in the mid cervical spine.
4. **TUCK** the elbow along the spine.
5. **TRACTION** down to the CT junction (restriction)
6. Sit back.
7. Lightly compress the underneath arm.
8. **TAKE** the patient over the TOP with you as you roll all the way over to the opposite ear-to-ear position.
9. Small body drop

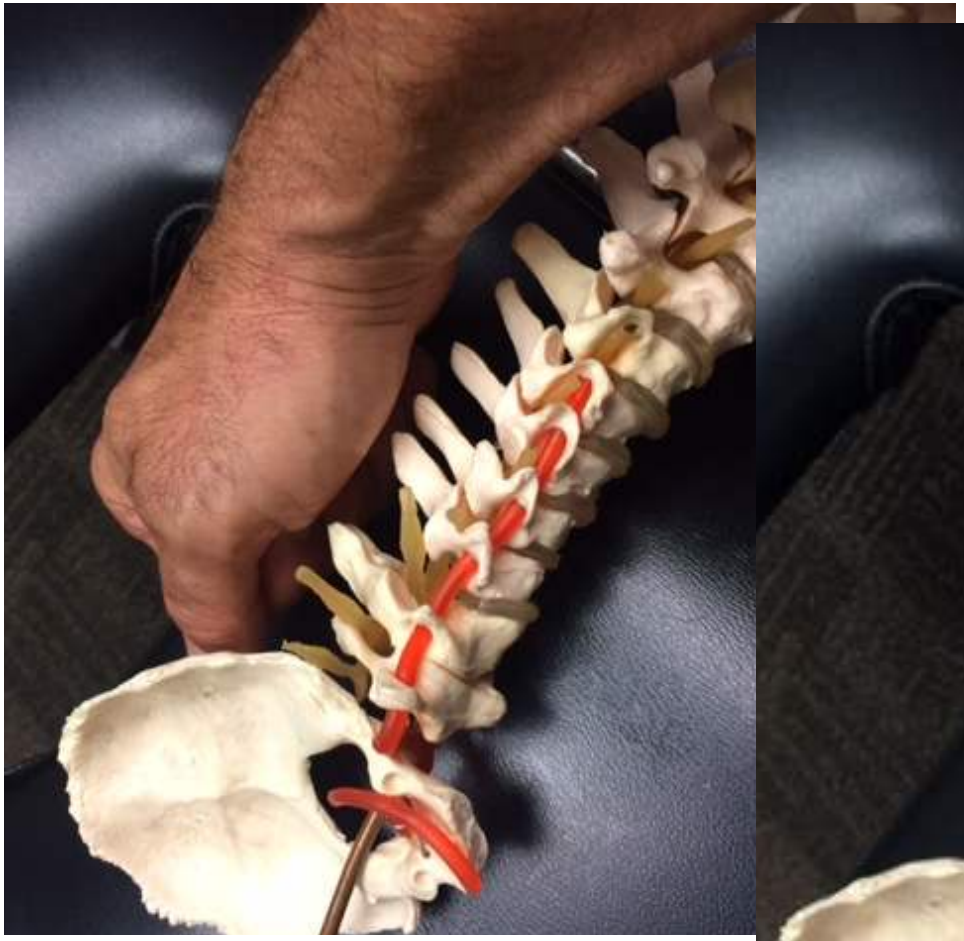

START TRACTION



FINISH TRACTION

Upper Thoracic / CT Adjustment







Procedure:

1. **Neutral Prone Position**
2. **Contact Hand – Thumb 1” from spinous process**
3. **Patient Rotates head away from contact**
4. **Tension created by lean & body weight**
5. **Indifferent Hand – zygomatic & mastoid .**
6. **Thrust straight across**

Upper Thoracic / CT Adjustment

Contact variables



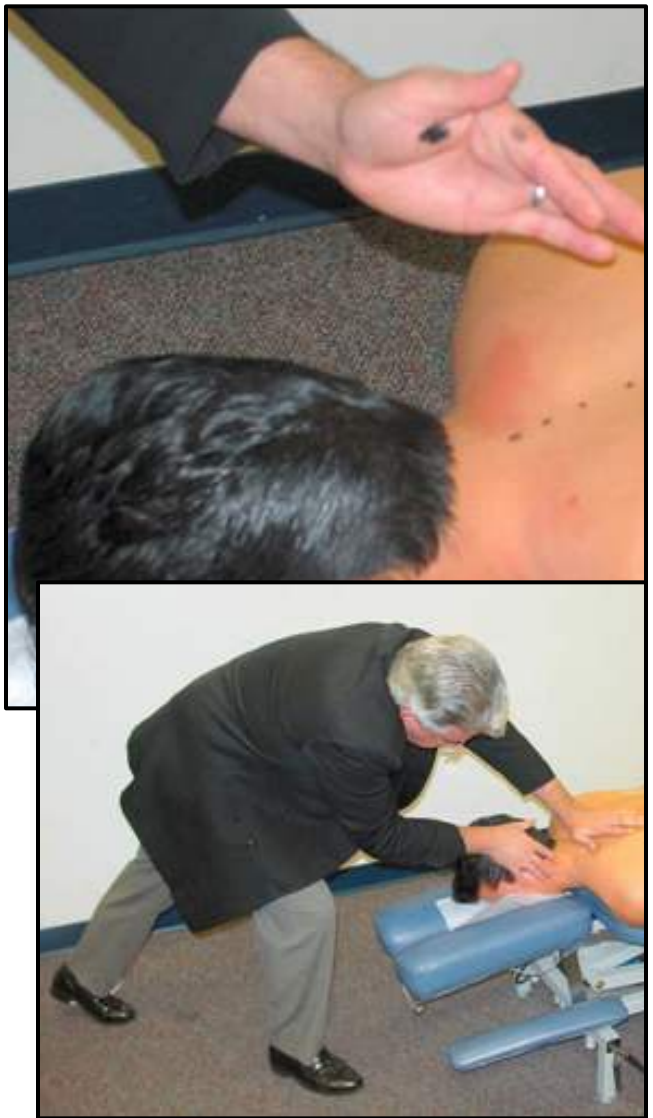

Lab 3

THE THORACOLUMBAR SPINE



LUMBAR SPINE FACET PLANES

- Due to relatively sagittal facet planes only 3 degrees of pure rotation is allowed (Bogduk, 1997)
- After 3 degrees of rotation, there is significant loading on the impacted facet and a lateral translation force on the disc (Bogduk, 1997)

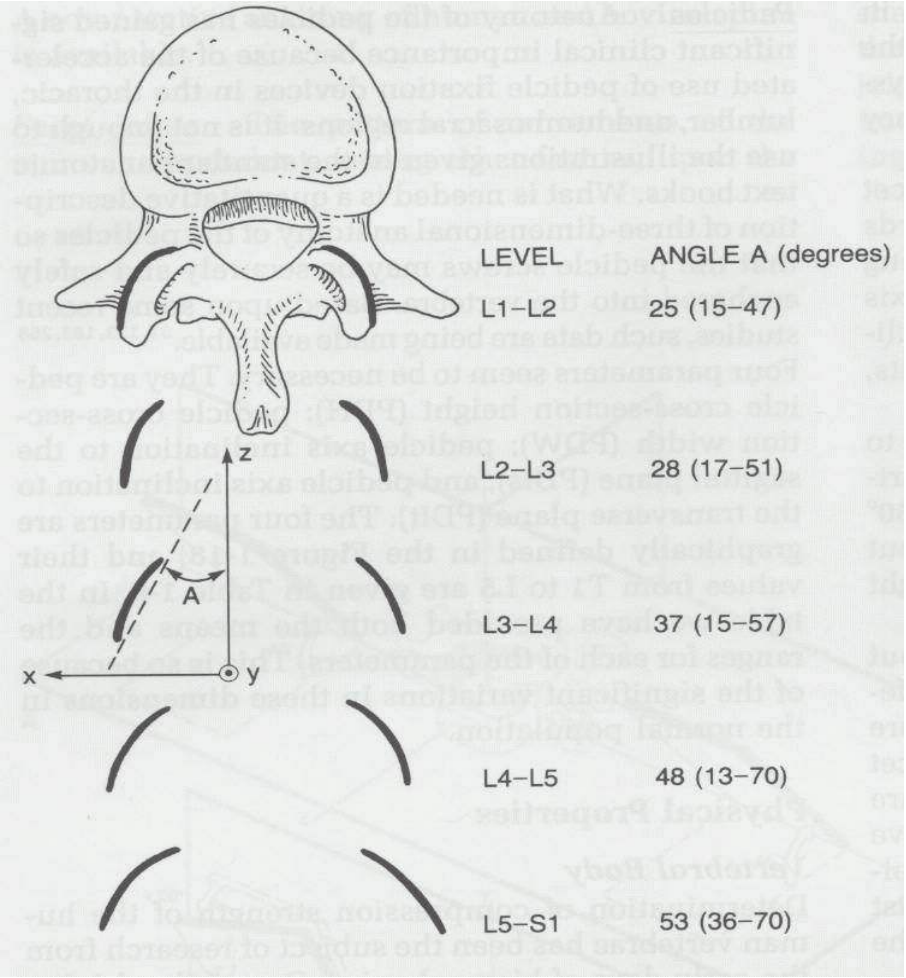





THE SPHINX

VISUAL KEYS:

- ✓ ASIS POSITION
- ✓ AMOUNT OF KYPHOSIS

SUBJECTIVE KEYS:

- ✓ NEW PAIN OR INCREASE IN PAIN?
- ✓ LOCATION?
- ✓ CENTRALIZATION?

PALPATION KEYS:

- ✓ PALPATING ARM STAYS RIGID
- ✓ SLIGHT BODY LEAN
- ✓ FLUID MOVEMENT
- ✓ FACE CRANIALLY FOR SACRUM
- ✓ PALPATION IS PERPENDICULAR TO THE SPINE ANGLE



LUMBAR SPINE MOVEMENT ANALYSIS

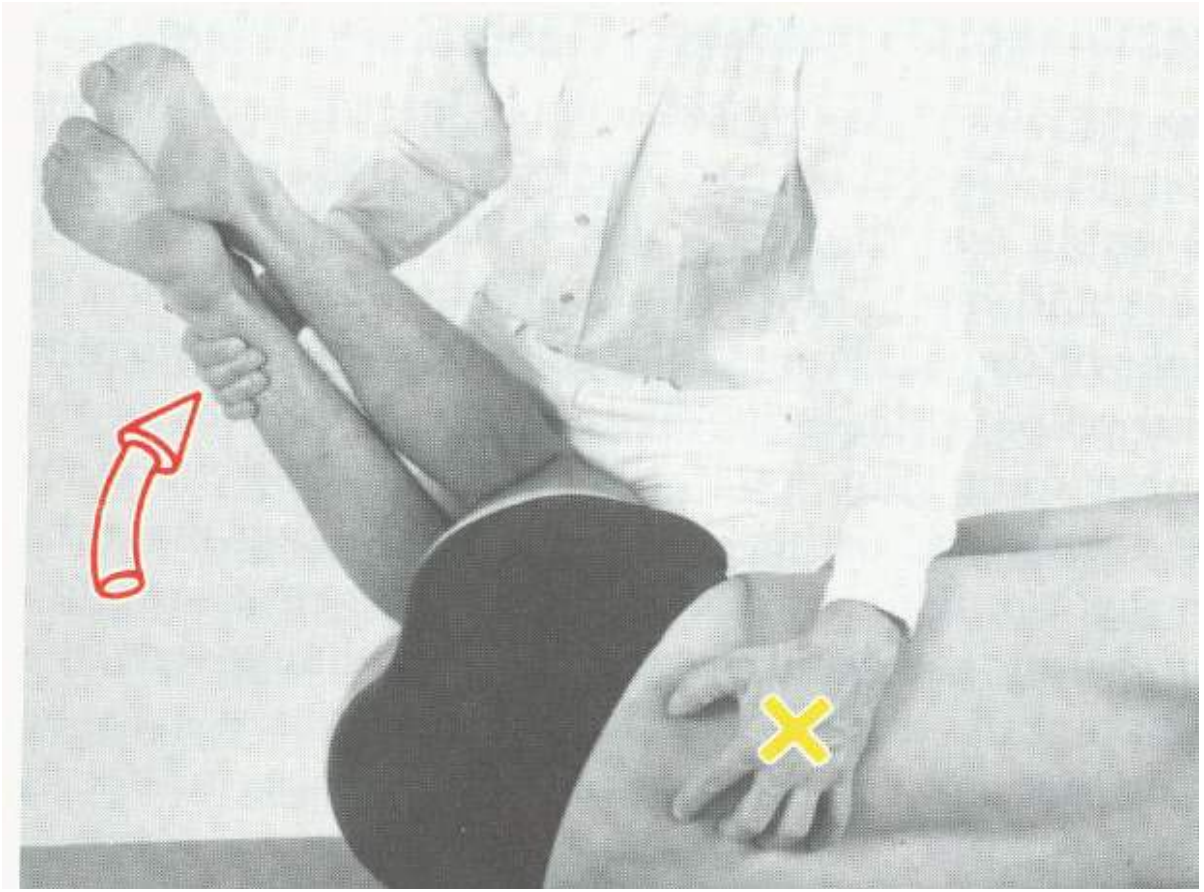

Lat flex & Rot

Flex/Ext

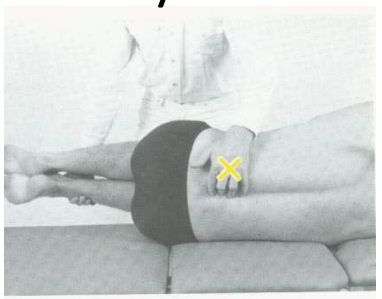

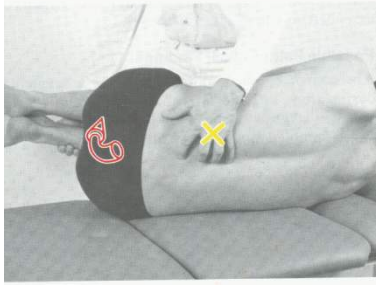

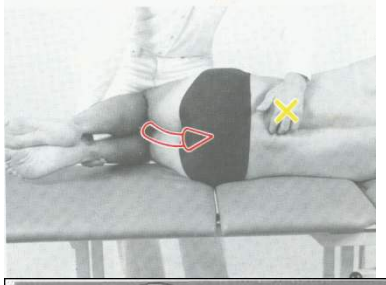

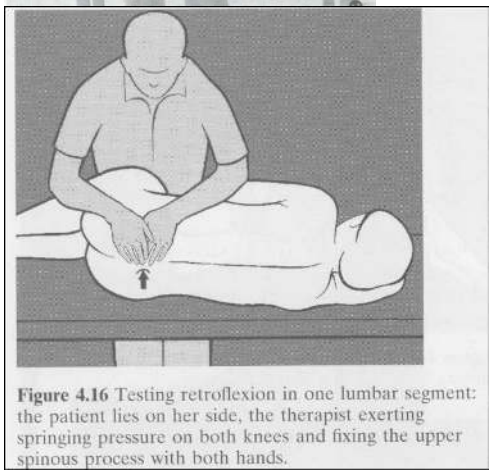

Figure 4.16 Testing retroflexion in one lumbar segment: the patient lies on her side, the therapist exerting springing pressure on both knees and fixing the upper spinous process with both hands.

Side Posture TL: Extension



Side Posture TL-Flexion

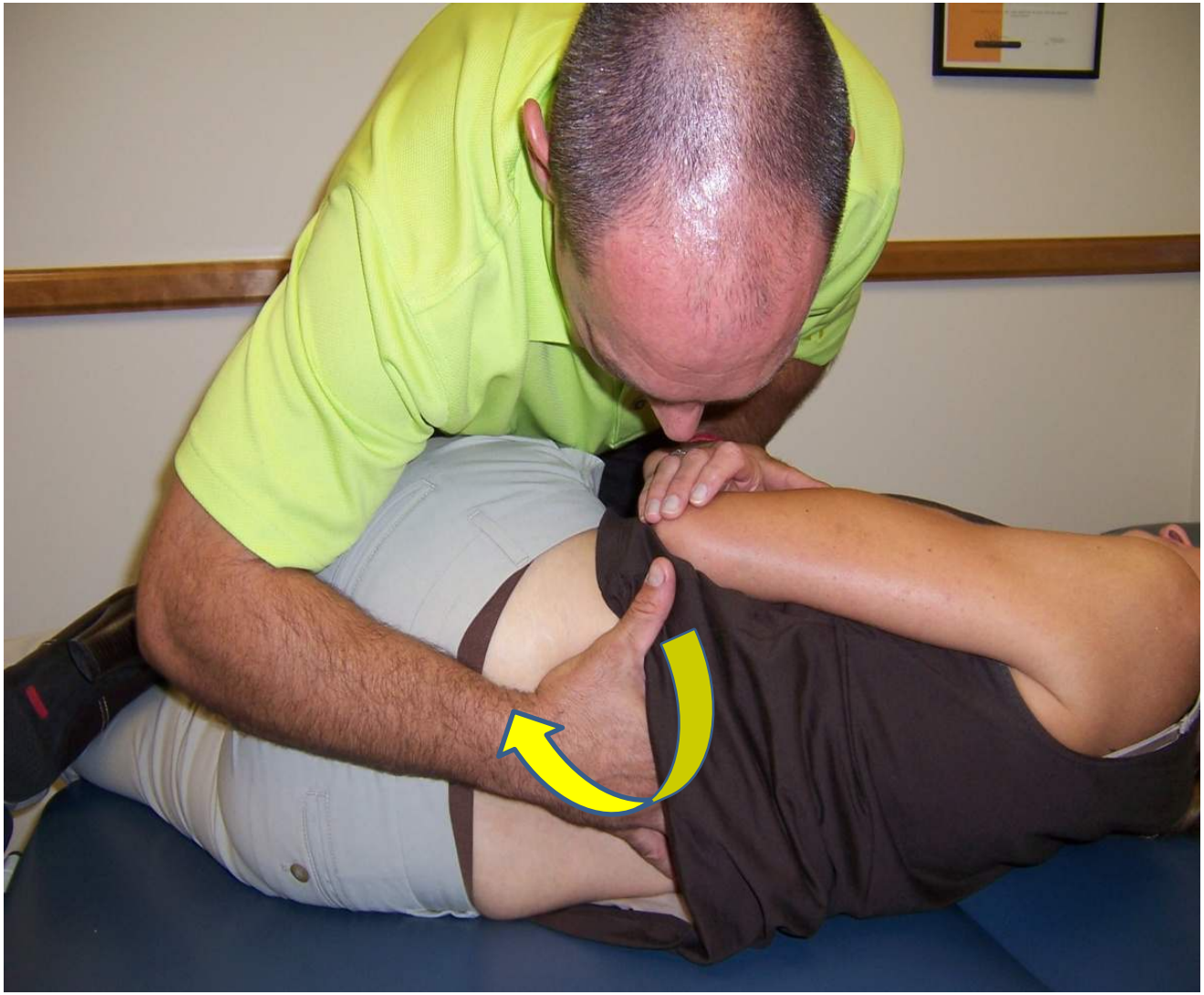

- Same patient set-up as CN of the sacrum.
- Contact-cupped hand (not the forearm)

Side Posture TL Kick Pull: Rotation/Lateral Flexion

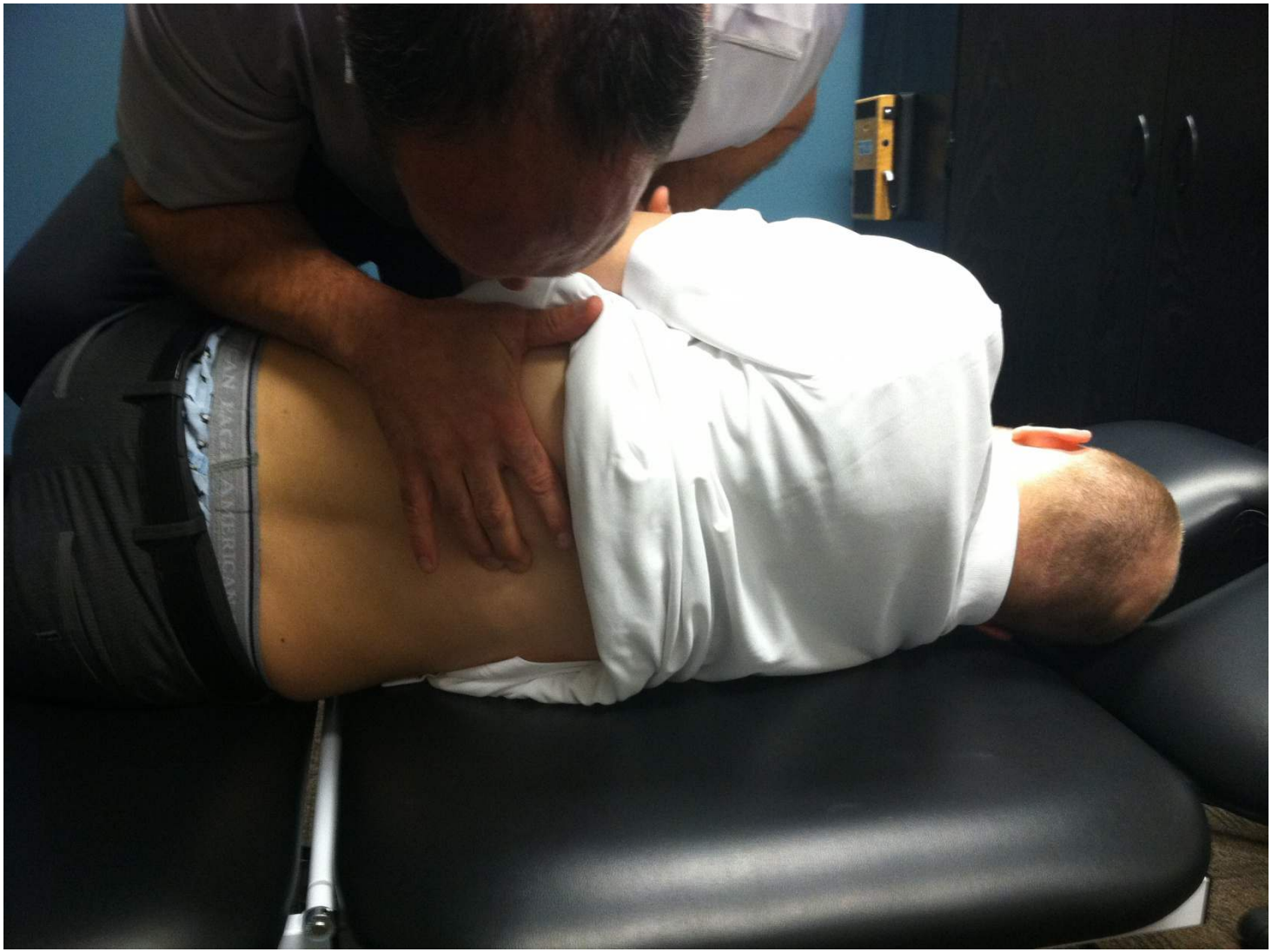

Side Posture TL Rotation/Lateral Flexion



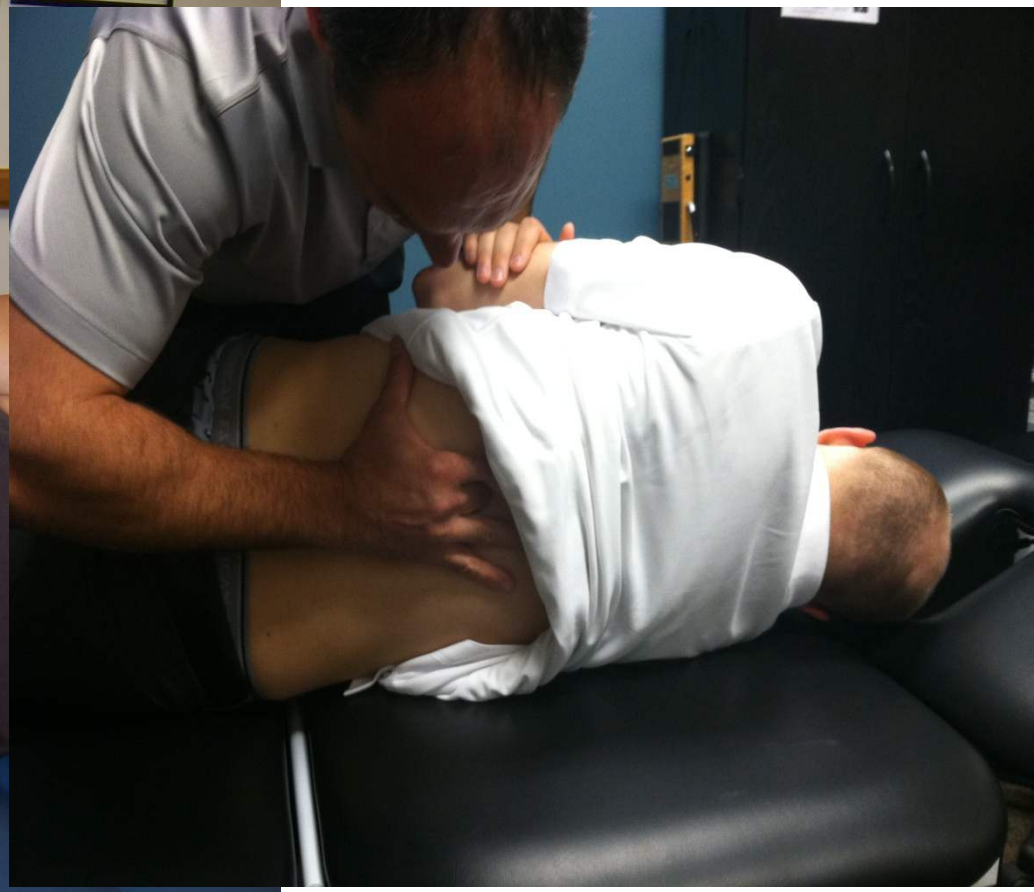

Bottom Leg Extended

Kick or Drop

Contact: 1. Soft Pisiform 2. Bent finger

Supine TL



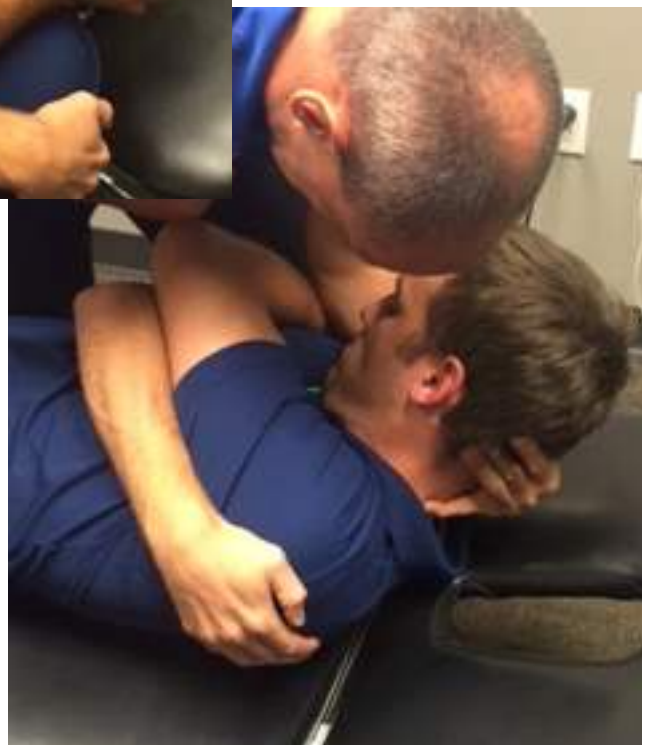

- Each step builds in a little more compression each time w/out losing the previous step.
- 1. Pts arm are crossed & tight
- 2. Traction lightly down w/ Dr arms on pts arms
- 3. Get ear to ear or pt forehead to dr shoulder asap
- 4.Sit back onto the table or do a small hip hinge.
- 5. Contact is a soft fist or open palm over the SP’s
- 6. Extension roll the patient onto the contact and start over the contact
- 7. Flexion- Keep the patient flexed and translate over your contact.

Supine TL



- Extension

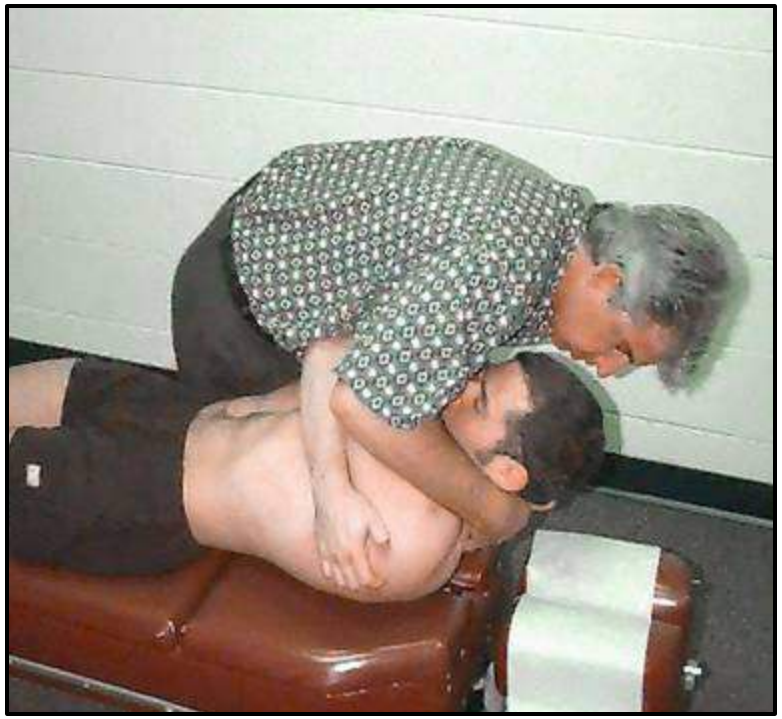

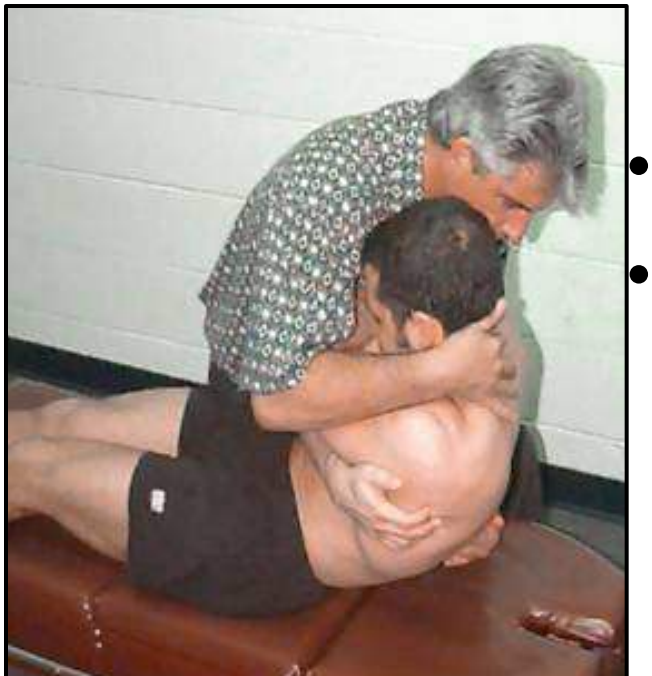

- Flexion
- Note: If you go to the same side you have to cantilever or “drop the anchor”…see demo.

Altered Breathing Patterns and Chronic Low Back Pain

Approximately 60 % of CLBP patients demonstrate altered motor control strategies, specifically relating to breathing patterns, during simple motor control tasks that challenge lumbar spine stabilization

Rousel, N. European Spine Journal; 2011

TL Spine & the "Abdominal Canister"

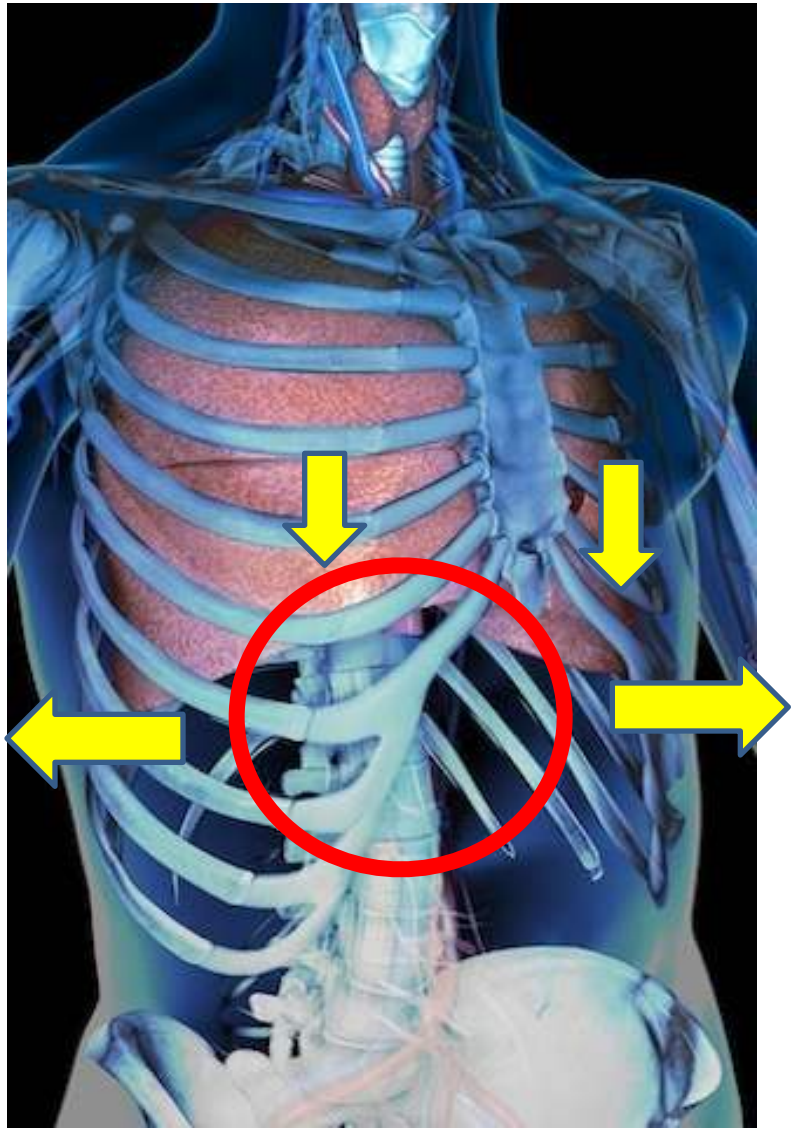

- The contribution of TrA to lumbopelvic stability involves increased IAP and fascial tension
- Changes in these parameters require co-activation of the diaphragm and pelvic floor
- Activity of these muscles occurs in conjuction with TrA during arm movements
- Hodges, 1999

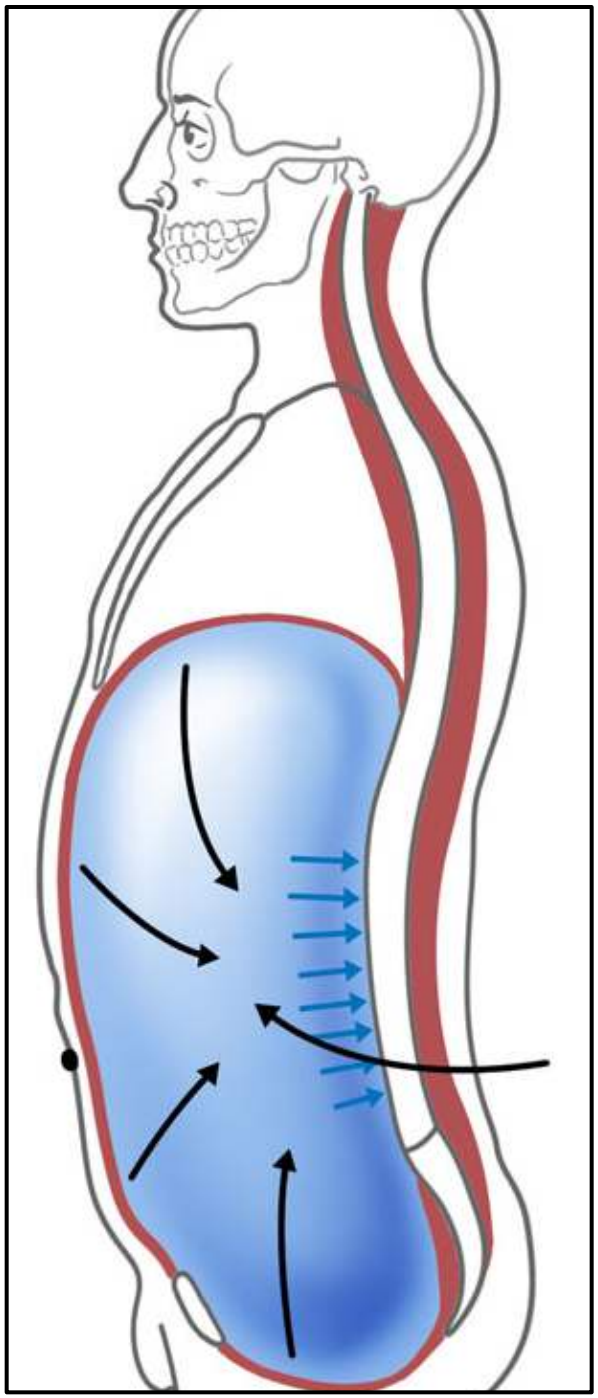

The low back is stabilized via intra-abdominal pressure

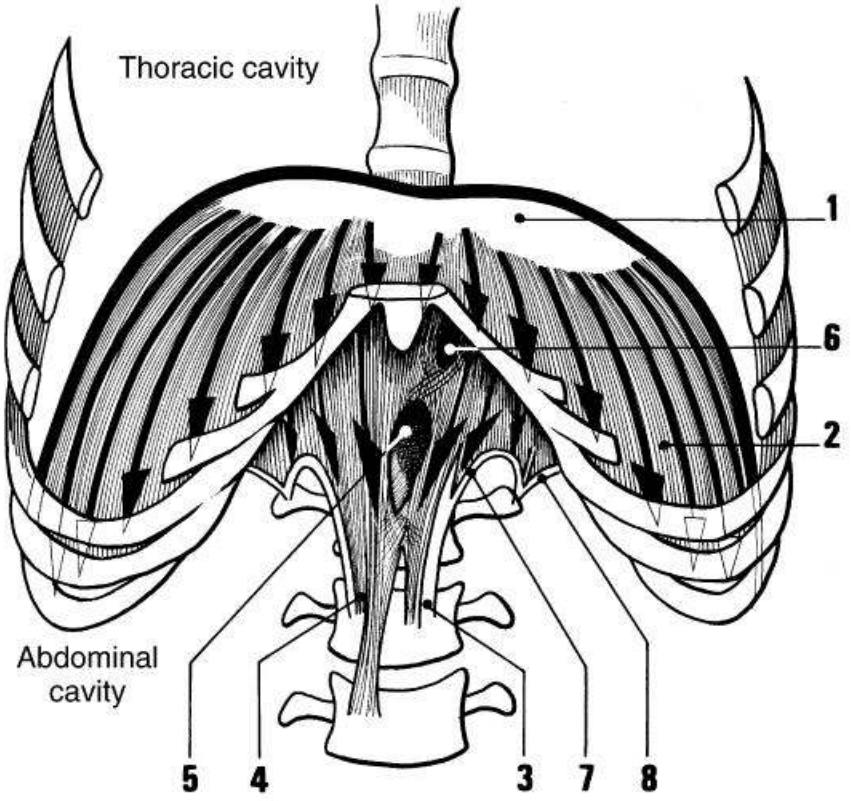

- **BACKGROUND: i**n 1989, a group of sixty-seven asymptomatic individuals with no history of back pain underwent magnetic resonance imaging of the lumbar spine. Twenty-one subjects (31%) had an identifiable abnormality o a disc or of the spinal canal. In the current study, we investigated whether the findings on the scans of the lumbar spine that had been made in 1989 predicted the development of low-back pain in these asymptomatic subjects.
- **RESULTS:** Of the fifty subjects who returned the questionnaire, twenty-nine (58%) hac no back pain. Low-back pain developed in twenty-one subjects during the seven-year study period. The 1989 scans of these subjects demonstrated normal findings in twelv a herniated disc in five, stenosis in three, and moderate disc degeneration in one. Eigh individuals had radiating leg pain; four of them had had normal findings on the origina scans, two had had spinal stenosis, one had had a disc protrusion, and one had had a disc extrusion. In general, repeat magnetic resonance imaging scans revealed a greate frequency of disc herniation, bulging, degeneration, and spinal stenosis than did the original scans.

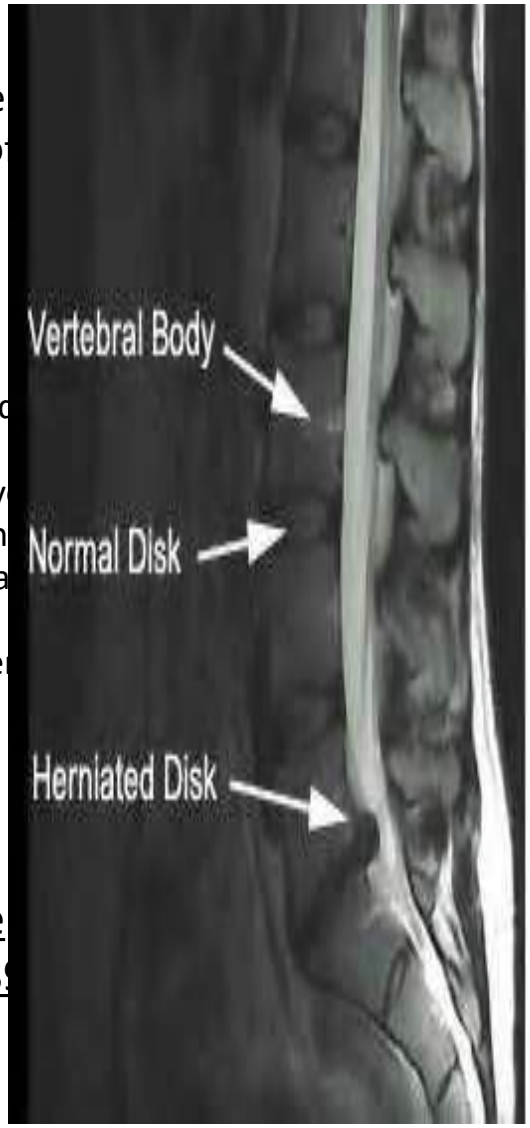

CONCLUSIONS: The findings on magnetic resonance scans were not predictive of the development or duration of low-back pain. Individuals with the longest duration of low-back pain did not have the greatest degree of anatomical abnormality on the original, 198 scans. Clinical correlation is essential to determine the importance of abnormalities on magnetic resonance images.

- J Bone Joint Surg Am. 2001 Sep;83-A(9):1306-11. **The value of magnetic resonance imaging of the lumbar spine to predict low-back pain in asymptomatic subjects : a seven-year follow-up study.** Borenstein DG, O'Mara JW Jr, et al

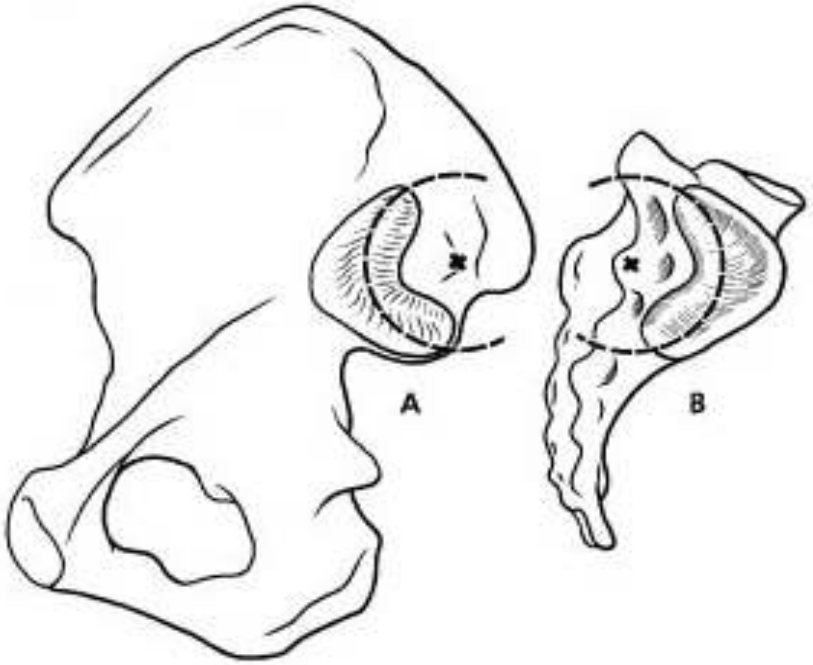

SACRO-ILIAC JOINT

*Palpation

*Adjustment

*Functional Assessment

*Active Care

ILIUM MOVEMENT IN GAIT

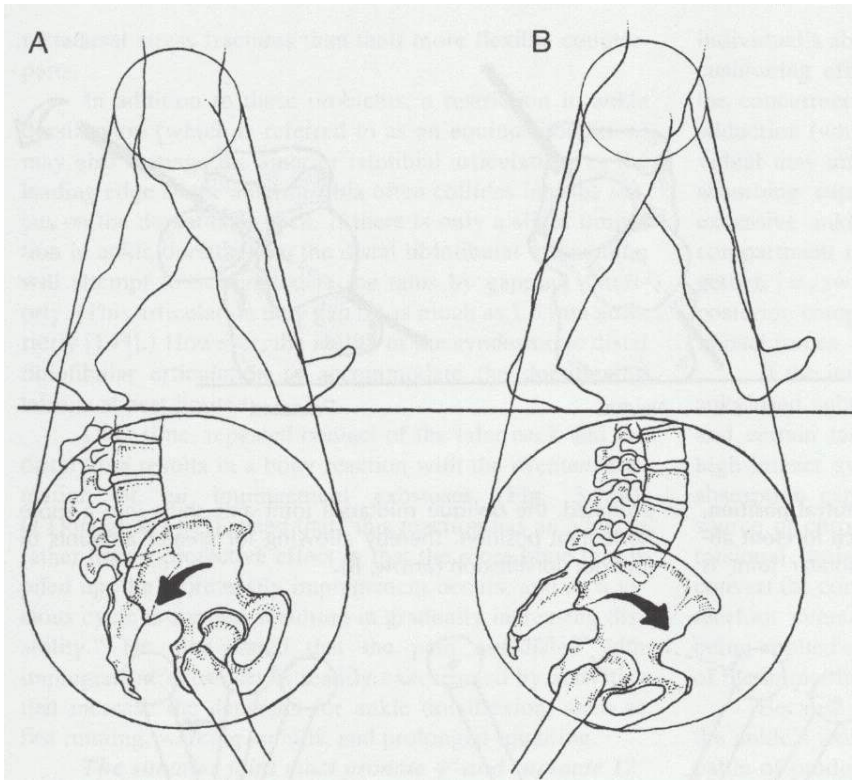

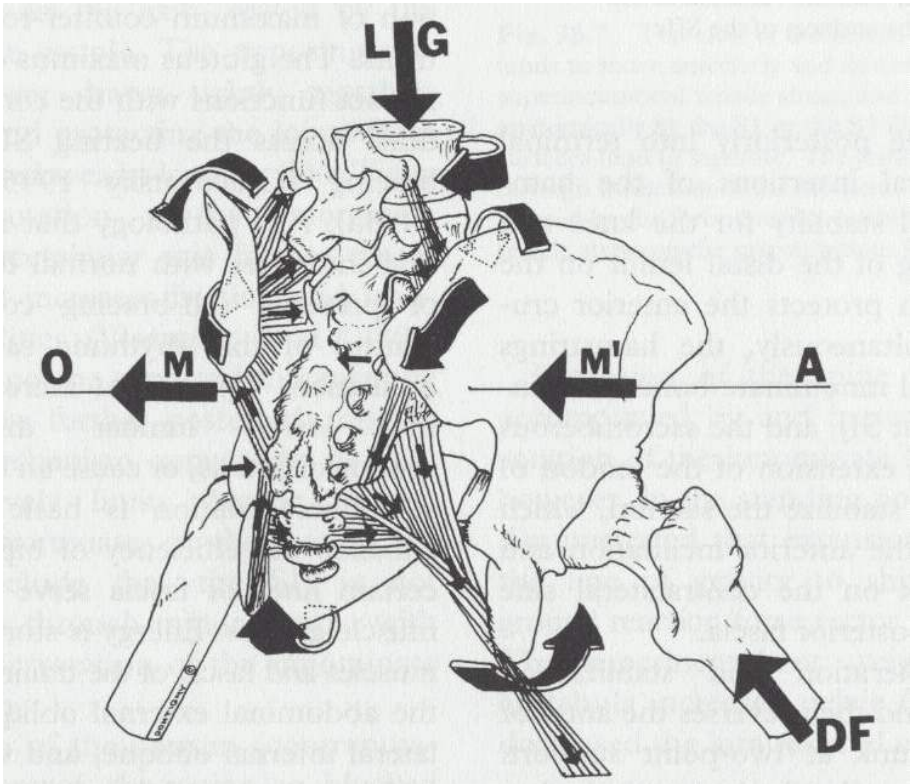

Fig. 38.9 On the side of initial impact the deceleration force (DF) and the pull of the hamstrings and sacrotuberous ligament create a force couple with a moment (M') that maintains self-bracing and stabilizes contralateral counter-rotation of the trunk. On the side of extension, the force couple is reversed creating a moment (M) that decreases self-bracing and releases stored energy. These two different moments result in an oblique axis of sacral movement (OA).

Palpation

This is doctor and patient positioning for checking the right iliosacral joint. The doctor's thumb is medial to the right PSIS and he laterally flexes the patient to the left and feels that joint space open; then joint play in a medial to lateral and P-A manner

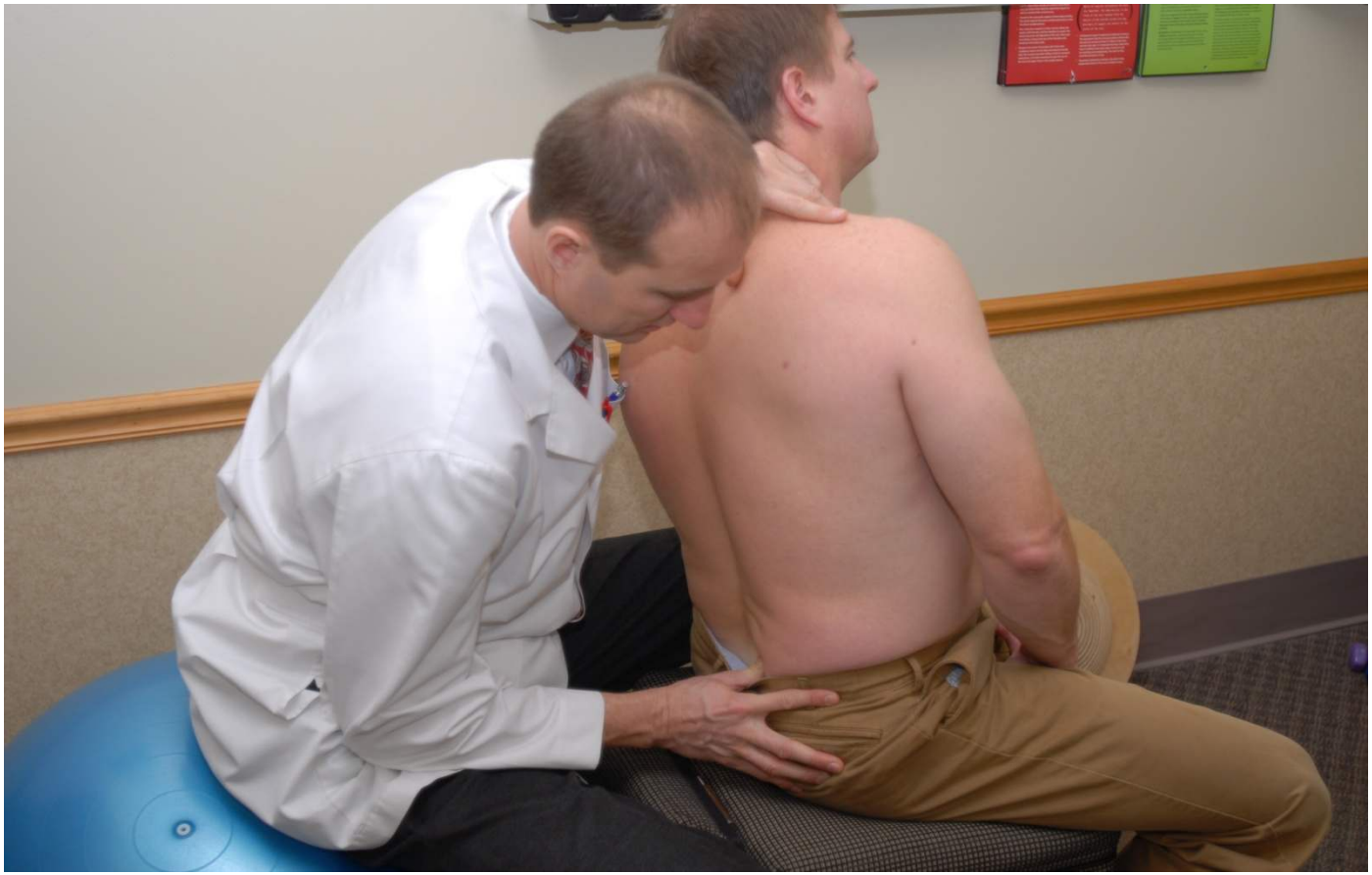

SIJ MOVEMENT ANALYSIS



Palpate over the SIJ.

Shear the knee slightly and feel for gapping under your hand.

Move the knee up into flexion and repeat



SIJ ADJUSTMENTS

- Kick- Pull: Pt. is neutral and stays that way. Double finger contact → Elbow is tucked→ Kick and pull happen almost simultaneously. 1.
- Drop: Patient alignment is neutral. Roll the patient far enough so the SIJ can be sheared. 2.
- Kick-Push: Pt. position is a mix between the first 2 adjustment. Kick and push happen almost simultaneous. Push is a quick pec contraction. 3.

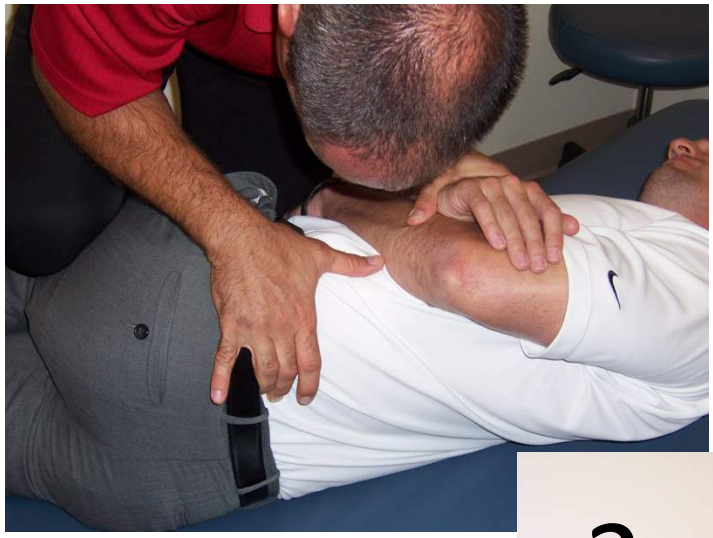

1.



2.



3.

Hip Flow

- SUPINE:

1. Passive hip flexion
2. FABERE
3. Impingement
4. Palpate Post. Capsule/SIJ



- Prone:

1. Hip Ext.
2. Int. Hip Rotation (hibbs)
3. Kinetic Chain tone assessment
4. Prone head extension.
5. Ant Hip capsule palpation. 6. SIJ palp 7. CN palpation

Hip Mobilization

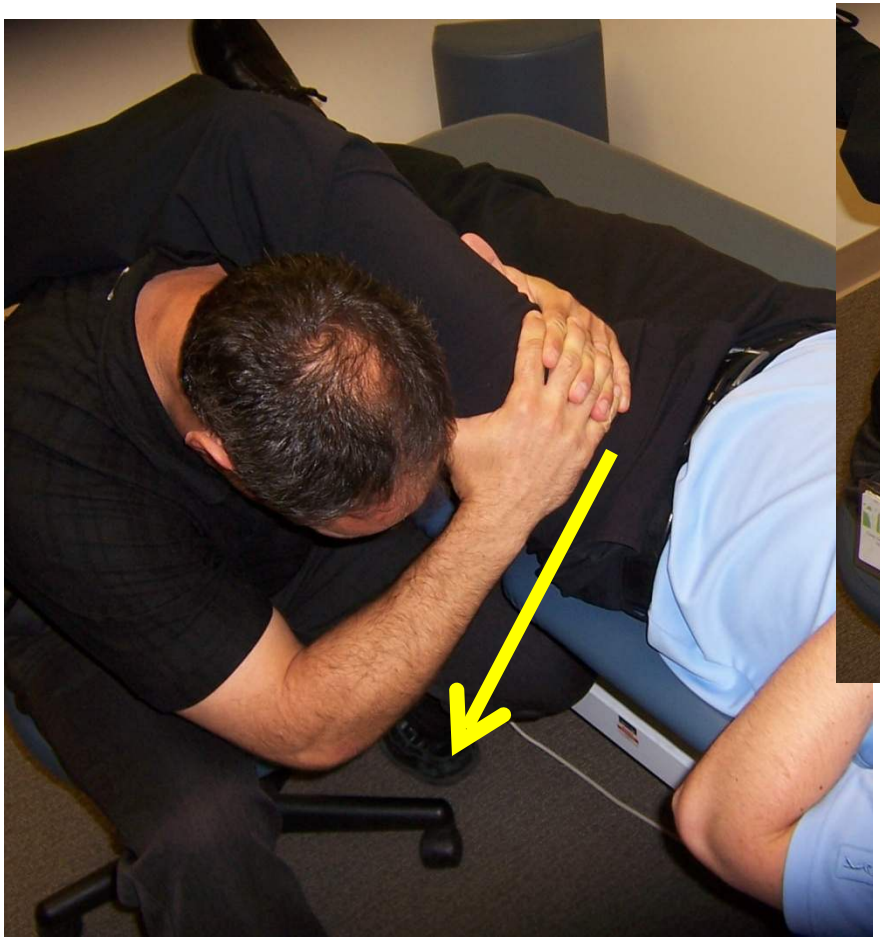

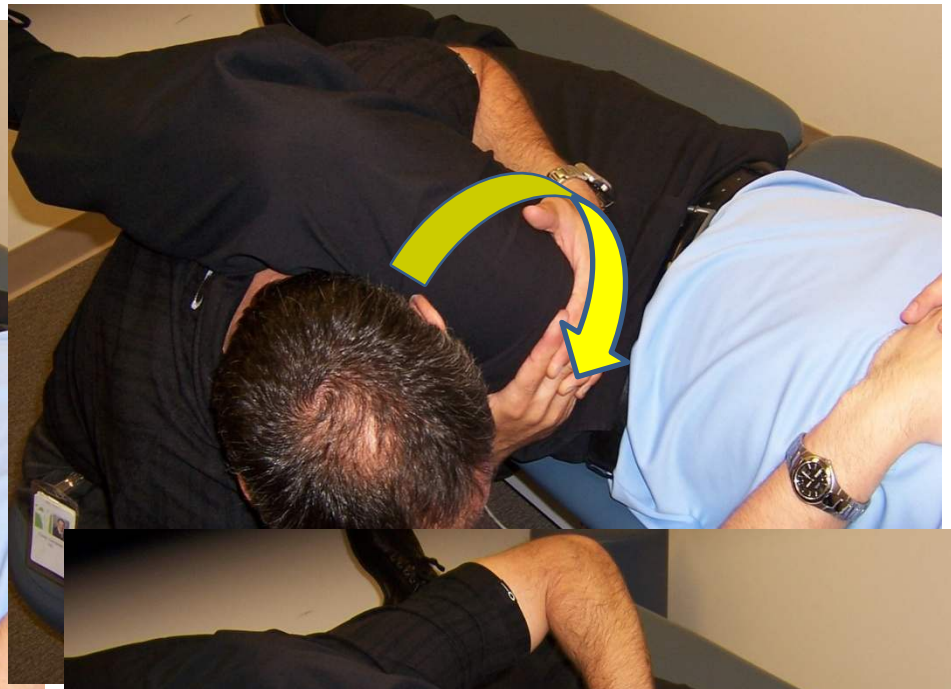



- Knee over the Dr. shoulder
  - 1. Distract and mobilize inferior to t floor
  - 2. Mobilize in a C-scoop into the posterior hip capsule.
  - 3. Mobilize in circumduction.

Anterior hip capsule mobilization/manipulation

PT: Prone

Action: Bend the knee, lift the knee while applying downward pressure at the gluteal fold.

Body drop with a locked arm into the drop piece.

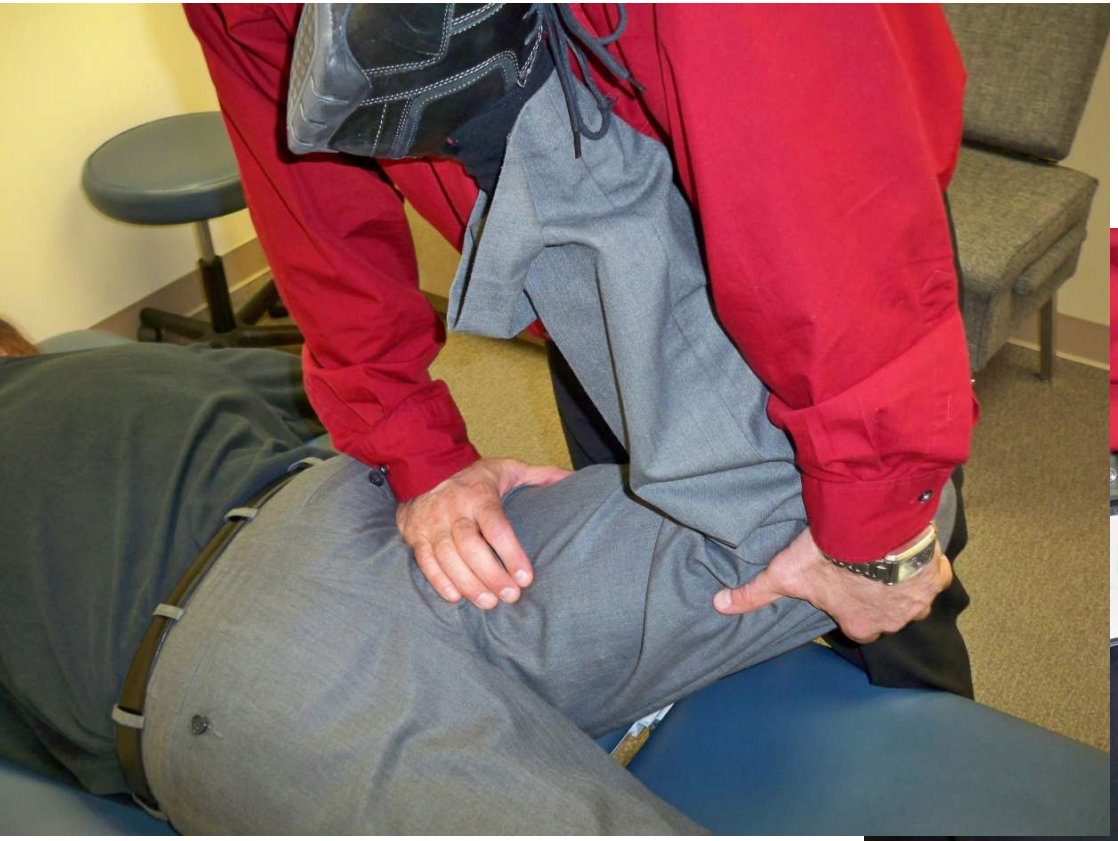

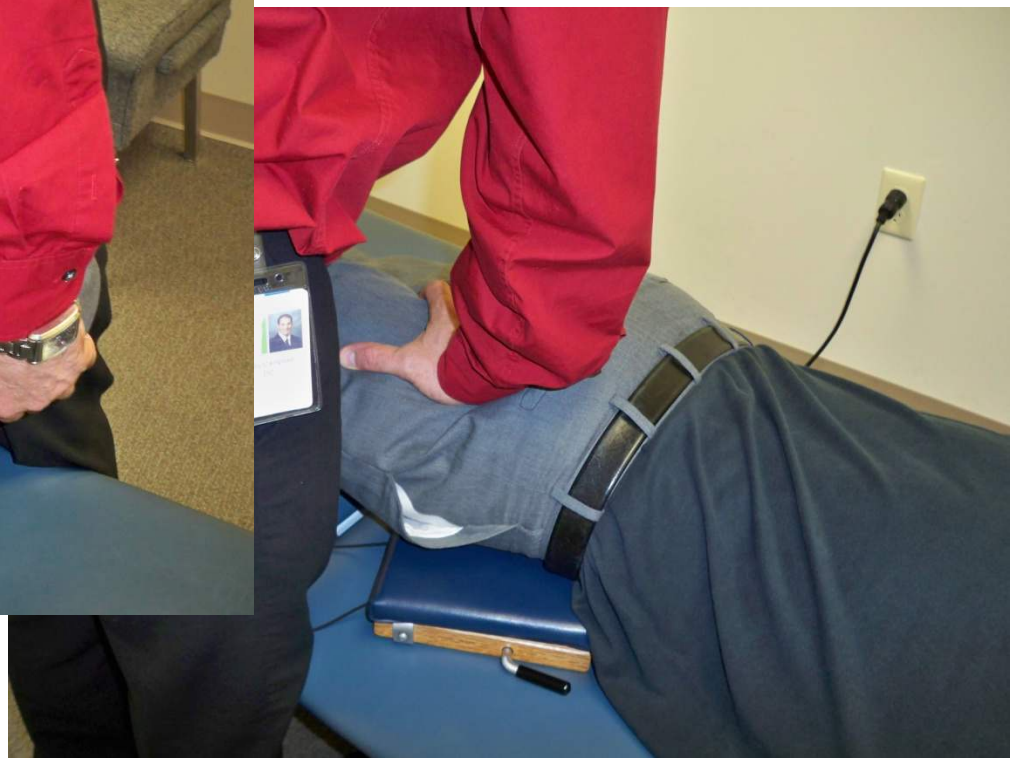

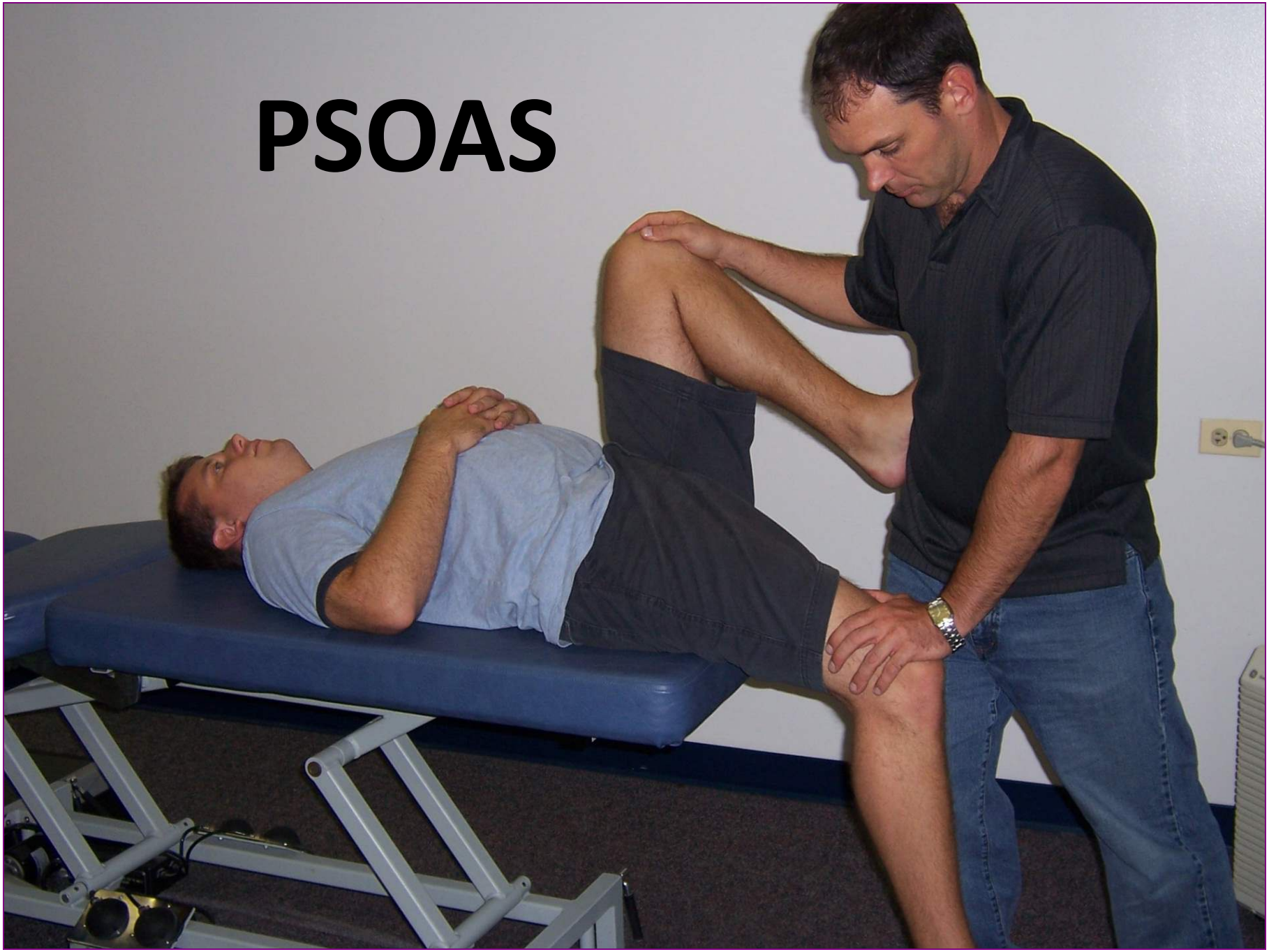
PSOAS

TFL

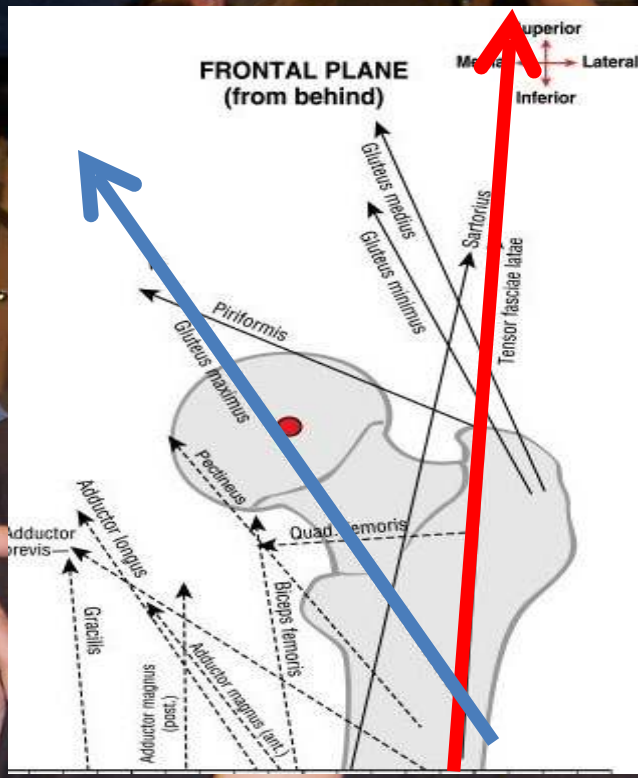
FRONTAL PLANE
(from behind)
Superior
Lateral
Inferior
Gluteus medius
Gluteus minimus
Sartorius
Tensor fasciae latae
Piriformis
Gluteus maximus
Pectineus
Adductor longus
Adductor brevis
Quad. femoris
Gracilis
Biceps femoris
Adductor magnus (ant.)
Adductor magnus (post.)
semitendinosus

6” Step Down



Starting position for the 6 inch step down. Knee stays over the first toes. Checking ankle mortis dorsiflexion, calcaneal eversion, and eccentric control of the femur via the G. Medius



This is the completion of the test for the 6” step down as the patient slowly lowers their right foot down with toes pointing up and lightly touches the right heel to the floor in a smooth and coordinated manner. For more advanced athletes, an 8” step down can be used.

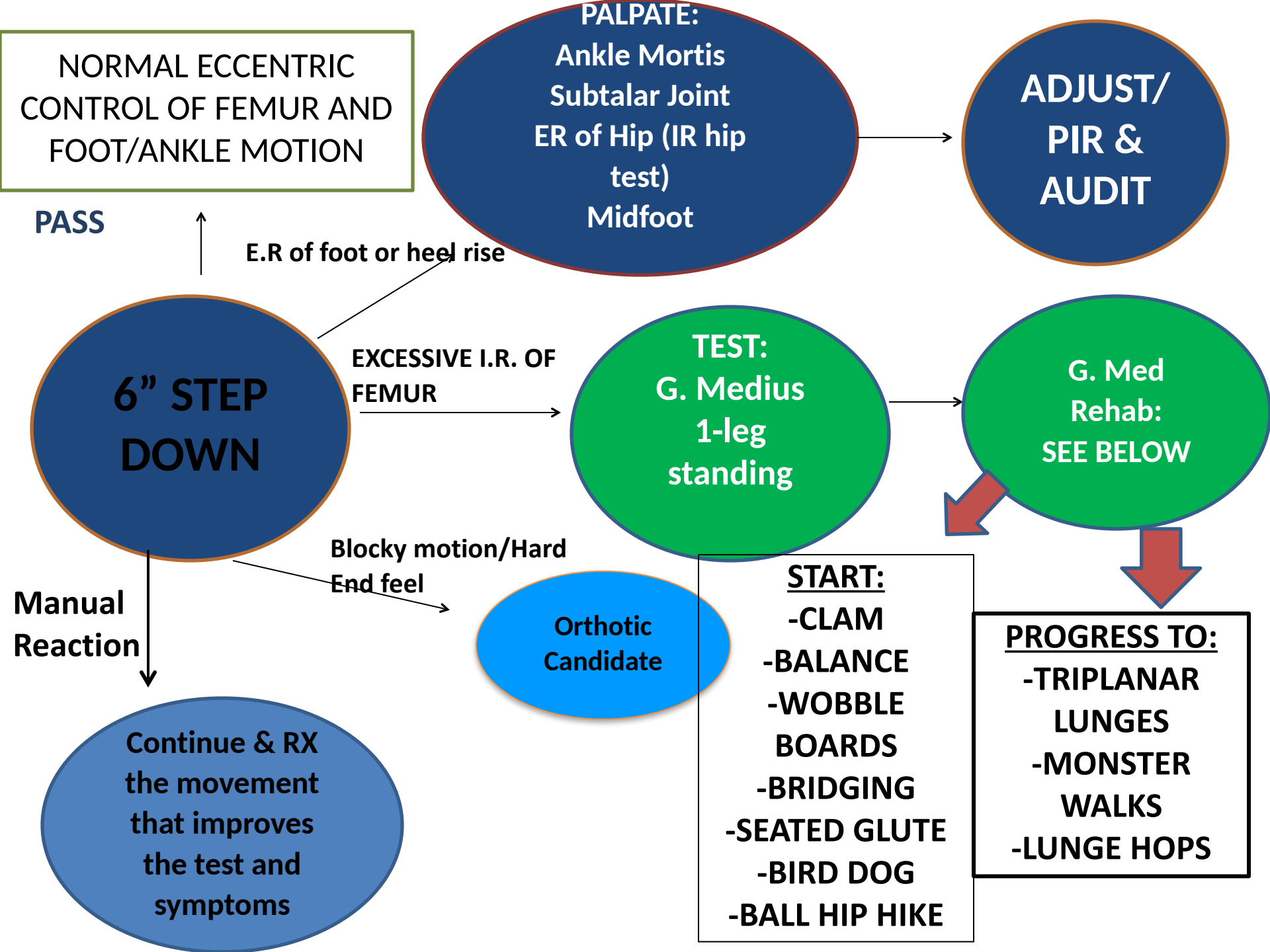
NORMAL ECCENTRIC CONTROL OF FEMUR AND FOOT/ANKLE MOTION
PALPATE:
Ankle Mortis
Subtalar Joint
ER of Hip (IR hip test)
Midfoot
ADJUST/ PIR & AUDIT
PASS
E.R of foot or heel rise
6" STEP DOWN
EXCESSIVE I.R. OF FEMUR
TEST:
G. Medius
1-leg standing
G. Med Rehab:
SEE BELOW
Blocky motion/Hard End feel
Orthotic Candidate
Manual Reaction
Continue & RX the movement that improves the test and symptoms
START:
-CLAM
-BALANCE
-WOBBLE BOARDS
-BRIDGING
-SEATED GLUTE
-BIRD DOG
-BALL HIP HIKE
PROGRESS TO:
-TRIPLANAR LUNGES
-MONSTER WALKS
-LUNGE HOPS

Hip screens and tests:

- Internal hip rotation→ structural abnormalities and fxnal limitations.
- Modified Thomas→ hip flexors
- Adduction-Impingement
- FABERE (can be better for SIJ) & Scouring→hip DJD or Labrum
- 6-inch step down/2-leg Squat→Eccentric capabilities of hip & foot mobility limitations.
- 1-leg stance→ balance/neuro
- 1-leg toe touches→function/neuro

INTERNAL HIP ROTATION

- Internal hip rotation
  - Unilateral loss was associated with SIJ (Cibulka, 1998)
  - Norm=40 degrees
- Hard end feel- think DJD of the hip or Retroverted hip
- Soft end feel could be:
  - SIJ
  - Deep external rotators (piriformis etc)



THE CLAM

*Limit pelvic rotation.

- Eccentric phase key.
- Self monitor for biofeedback.
- Standing variations.
- THE GOAL IS GLUTE ACTIVATION WITHOUT TFL ACTIVATION WHICH TAKES CUEING AND TRAINING!!

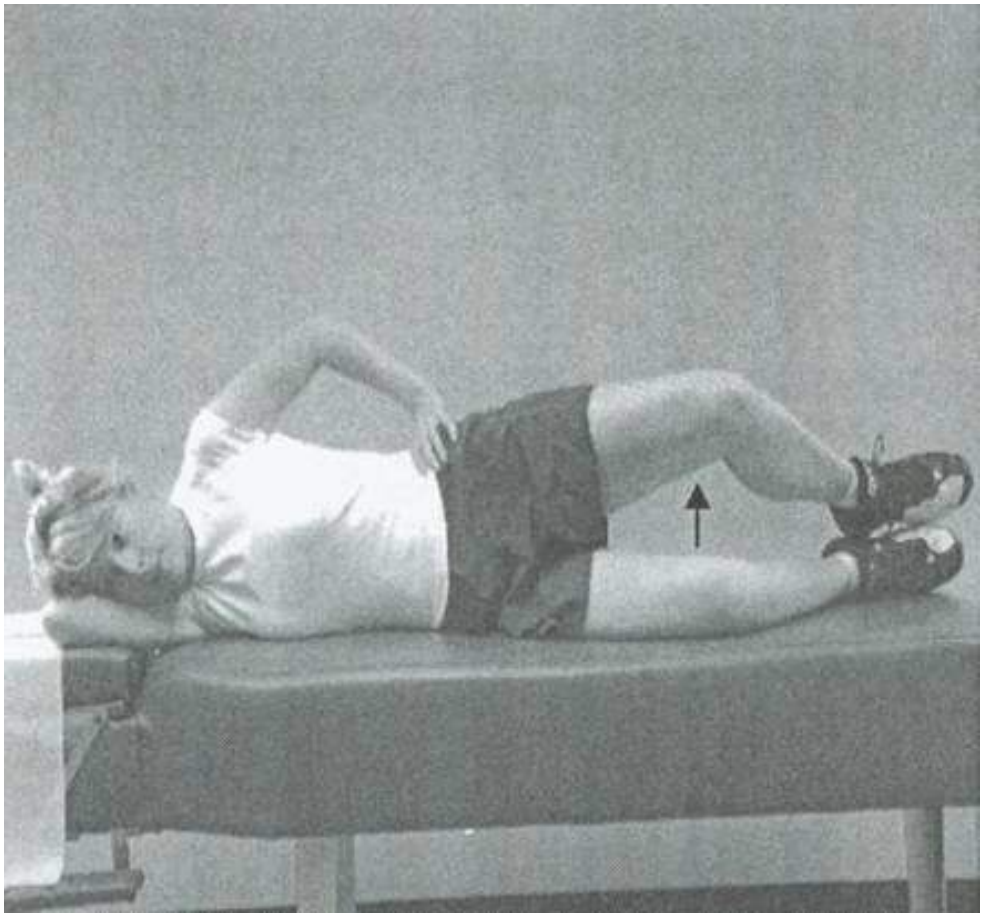

Indications: Failed single leg stance
Excessive valgosity on 6 inch step down
Hypermobility with palpation/>80 degrees IR Hip

Day 1 Glute Rehab



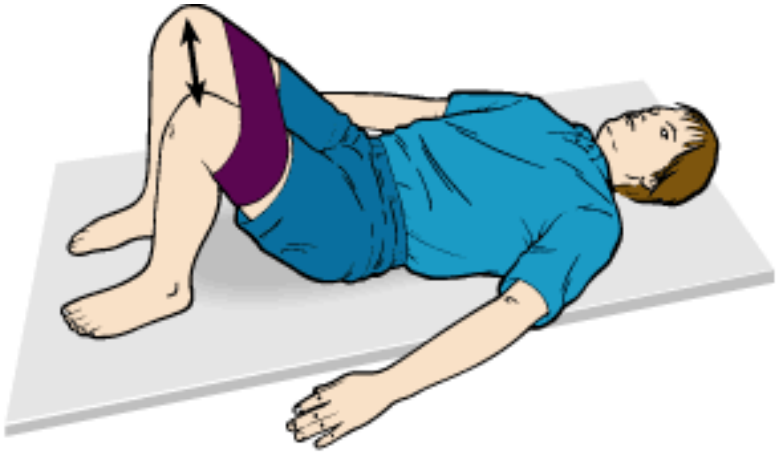

Bridge options: Feet on the floor. Widen out→ push feet into the mat→ bridge up.

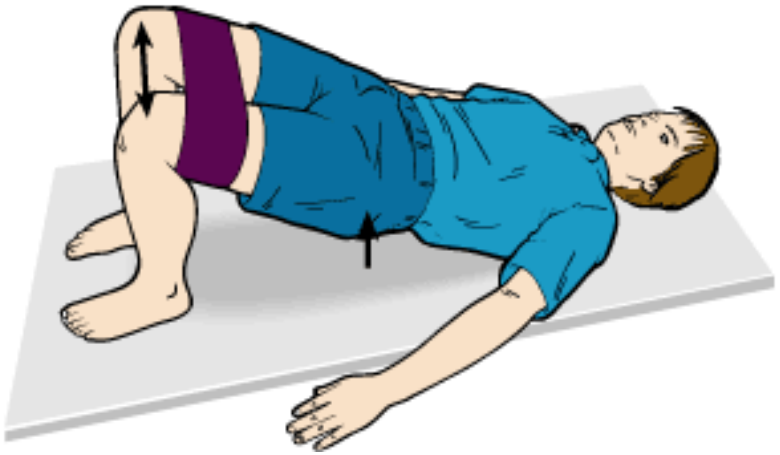

Ball: Allow the feet to roll out sli

Indications: Failed single leg stance
Excessive valgosity on 6 inch step down
Hypermobility with palpation

Stabilization…Plus

Resistance is from inside to out.
*Foot can flare but still respect the tripod of the foot.
*Abduct and Supinate
*Slowly return to foot neutral.
*RX: 3-4 sets 8-10 reps before activity &
again 3 times during the week for 4 weeks.

Stabilization…Plus

Hip Roll to Side Bridge

(monitor rec fem tension on support leg)





Side Bridge Reach w/w/o theraband





Hip Stability Plus

Stand Up/Sit Back/Cork Screw



<u>Option</u>: Move from kneeling position to partial stand-up. Focus on glute/hip of front leg. Move slowly upwards and control eccentric lowering phase.

Can add band under left knee/in right hand. Reach.



Monitor rec fem tension on support leg.

Functional Reaches

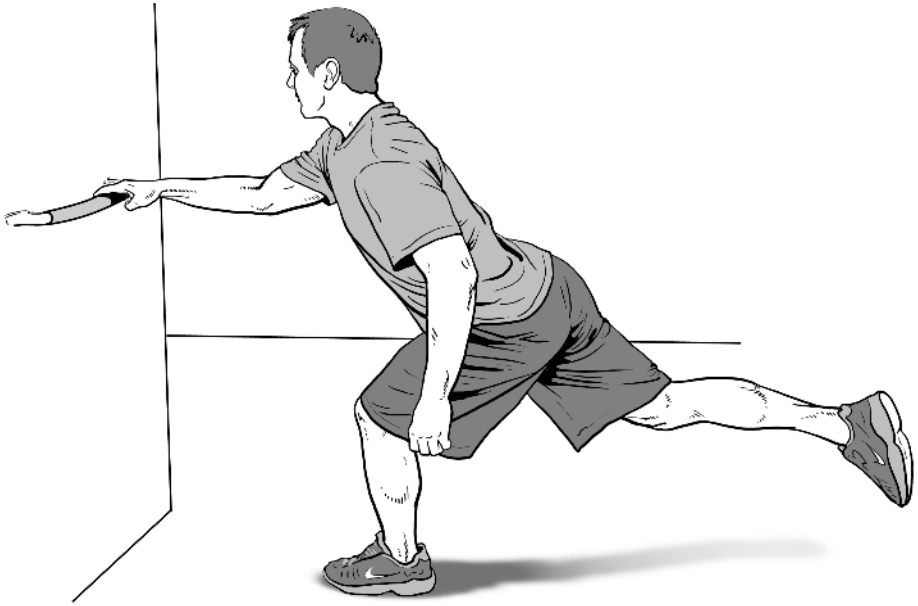

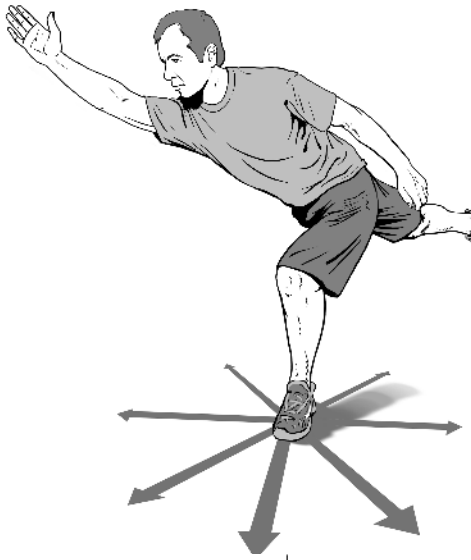

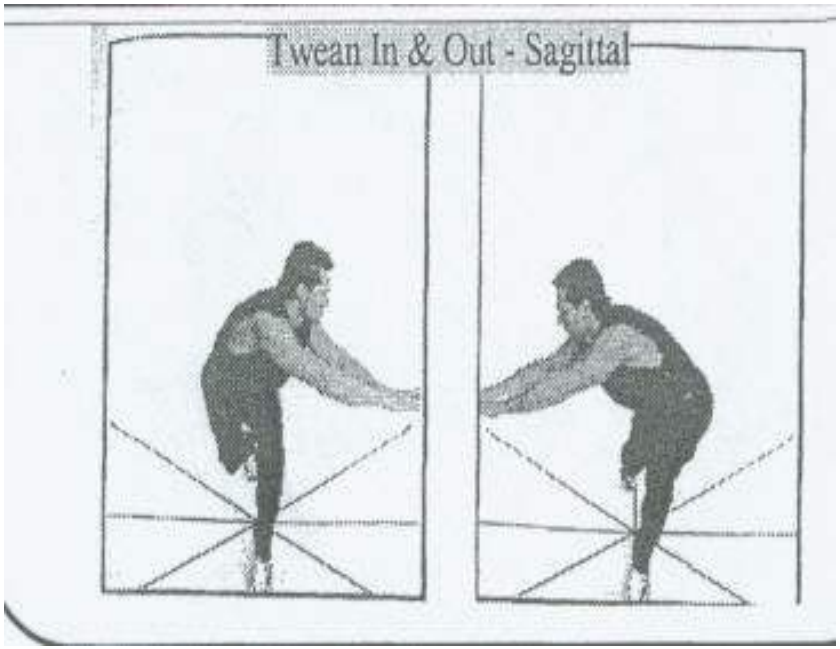



HIP F.I.T

- Side step with or without resistance.
- Addresses the frontal plane functionally.
- Add flexion or extension bias based on your patient
- Indication: Excessive frontal plane motion during gait. 1-leg standing –compensating Trendelenburg

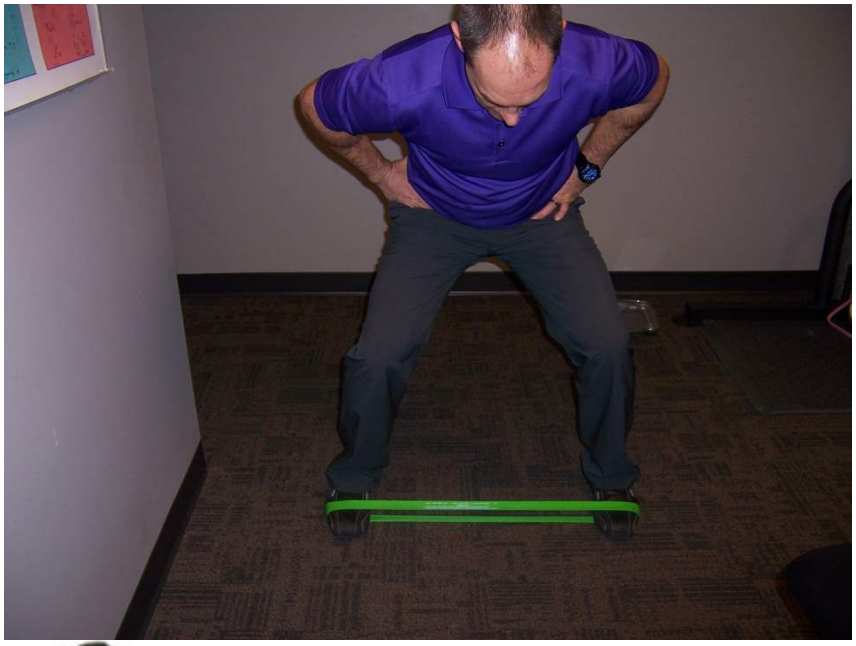



CHIROPRACTIC SUCCESS

- How is success measured?
  - Patient Visits?
  - Monthly Income?
  - Size of the practice?
  - Results?
  - Patient Happiness?
  - DC Happiness?
- What is Success to you?
- How do you get there?
- Growth?
- Learning?
- Passion?
- Niche?
- Balance? (cognitive/ heart)
- Fulfillment.

” Success and Achievement without Fulfillment is the ultimate failure.”
Tony Robbins

Fixed



- Quick to quit.
- Cope destructively or shut off.
- Look for quick fixes.
- Multitask.
- Master of none.
- Old dog/ no new tricks.

Growth



- Excited when a challenge arises.
- View stress as growth.
- Focus.
- Put emphasis on “figuring it out”.
- Gritty and gracious.
- Feel potential has no ceiling
- Love to learn new things (comfort zone?)

FLIP the Script

- Focus-
- Love-
- Intent-
- Presence-


“It is time for the chiropractor to expand his tools and take more responsibility for the whole patient and how he functions in our society”
Karel Lewit, Motol Hospital, Prague, 2004

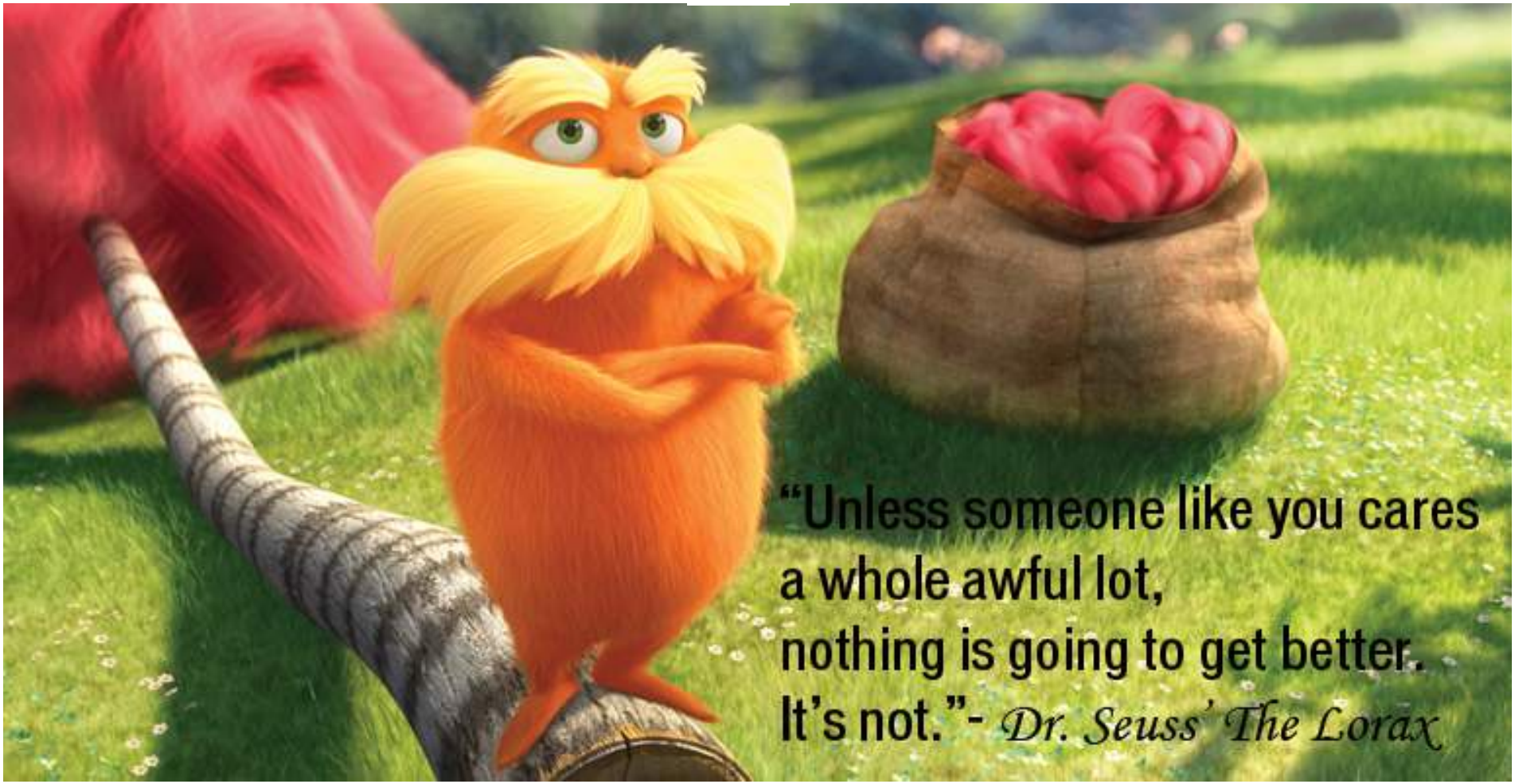
"Unless someone like you cares
a whole awful lot,
nothing is going to get better.
It's not."- Dr. Seuss' The Lorax

5 FOR THE ROAD

1. **What if your payment was directly tied to your presence, compassion and focus?**
2. **SMART Goals are dumb…set BIG goals.**
3. **Make monthly challenges that take you out of your comfort zone or improve your life.**
4. **Write out 3 things you can do to push your life forward and 3 things you are grateful for… EVERY DAY.**
5. **ACT. Don’t let your dreams die in the daylight. GRIT, GRACE, & GRATITUDE**

CHIROPRACTIC MANIFESTO

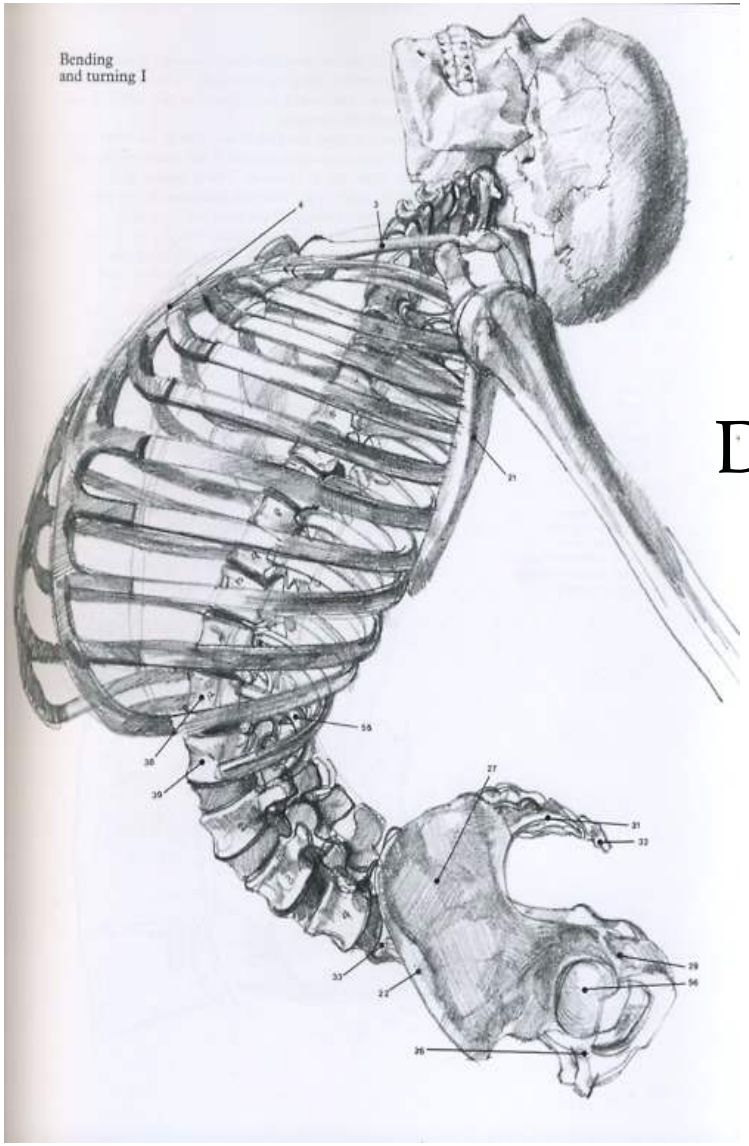

Revel in the Grind

Do NOT Make Excuses for Who Are & What You Stand For

Serve with Enthusiasm and Certainty & Advance with Abandon

The Motion Palpation Institute

MPI can give you the tools and direction you need to build the practice of your dreams.

The rest is up to you.

MOTION
PALPATION
INSTITUTE